

The bicoronal approach for the treatment of a large frontal sinus osteoma. A technical note

Marina Savastano, MD^{a,*}, Luca Guarda-Nardini, MD^b,
Gino Marioni, MD^a, Alberto Staffieri, MD^a

^aSection of Otolaryngology, Department of Medical and Surgical Specialties, University of Padua, Padua, Italy

^bUnit of Maxillofacial Surgery, Department of Medical and Surgical Specialties, University of Padua, Padua, Italy

Received 1 September 2006

1. Introduction

Osteoma represents the most common benign neoplasm of the nose and paranasal sinuses. The frontal sinus is the most frequent localization of osteoma in paranasal sinuses, with an incidence ranging from 37% to 80% of the cases, (followed by the ethmoid, maxillary, and sphenoid sinuses, respectively) and a predilection for the fifth and sixth decades (male-female ratio, 1.3:1) [1-4]. Thirty-seven percent of the cases of frontal osteoma involve the rhinofrontal duct, and 21% involve the superior-lateral side of the rhinofrontal ostium [5]. Tumor mean diameter may vary from 1.5 to 30 mm.

Sinonasal osteoma growth is usually very slow and may take many years to become clinically evident. Nevertheless, it may be locally aggressive, with displacement of anatomic structures and possible intracranial involvement such as rhinoliquorrhea, pneumocephalus, and intracranial infection [6]. Osteoma of the frontal sinus often requires a surgical treatment that depends on patient symptoms; tumor size, course, and location; and complications. Asymptomatic patients can be managed conservatively or submitted to surgery regardless of the location or extent of the tumor. Facial pain, facial deformity, and headache are symptoms that indicate a surgical approach. The growth rate of this benign tumor is very slow, but when its size provokes obstruction of the sinus ostia, extension into adjacent bones, intracranial cavity, and displacement of anatomic structures, the surgical approach is mandatory [7,8].

The present report describes the results of a bicoronal approach for the radical excision of a large frontal sinus osteoma. The results of this technique are compared with those of other surgical approaches.

2. Case report

The patient, a 44 year-old Caucasian man, has come to our observation because of an increasing headache affecting the left frontal orbital region. Three years before, the patient had undergone septoplasty for nasal obstruction, and a

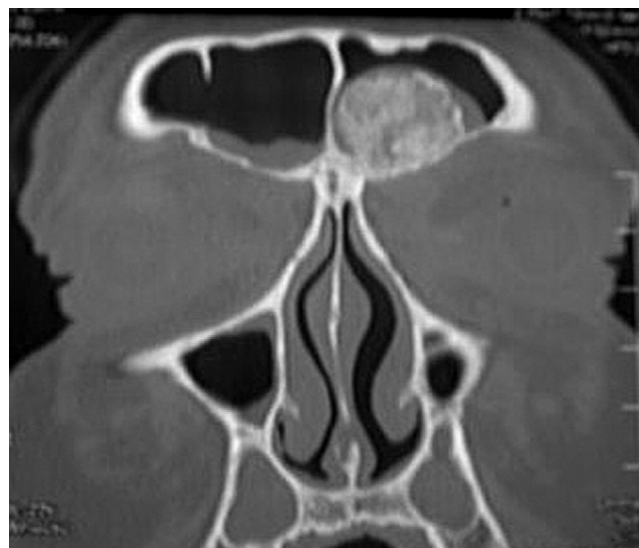

Fig. 1. CT scan (coronal view) of the 30-mm osteoma in the medial region of the frontal sinus.

* Corresponding author. Section of Otolaryngology, Department of Medical and Surgical Specialties, Padua University, 35127 Padova, Italy.
E-mail address: marina.savastano@unipd.it (M. Savastano).

paranasal sinus computerized tomography (CT) scan had shown an opaque, compact formation involving almost all of the left frontal sinus. During our evaluation, a new CT scan of the paranasal sinuses showed right deviation of the

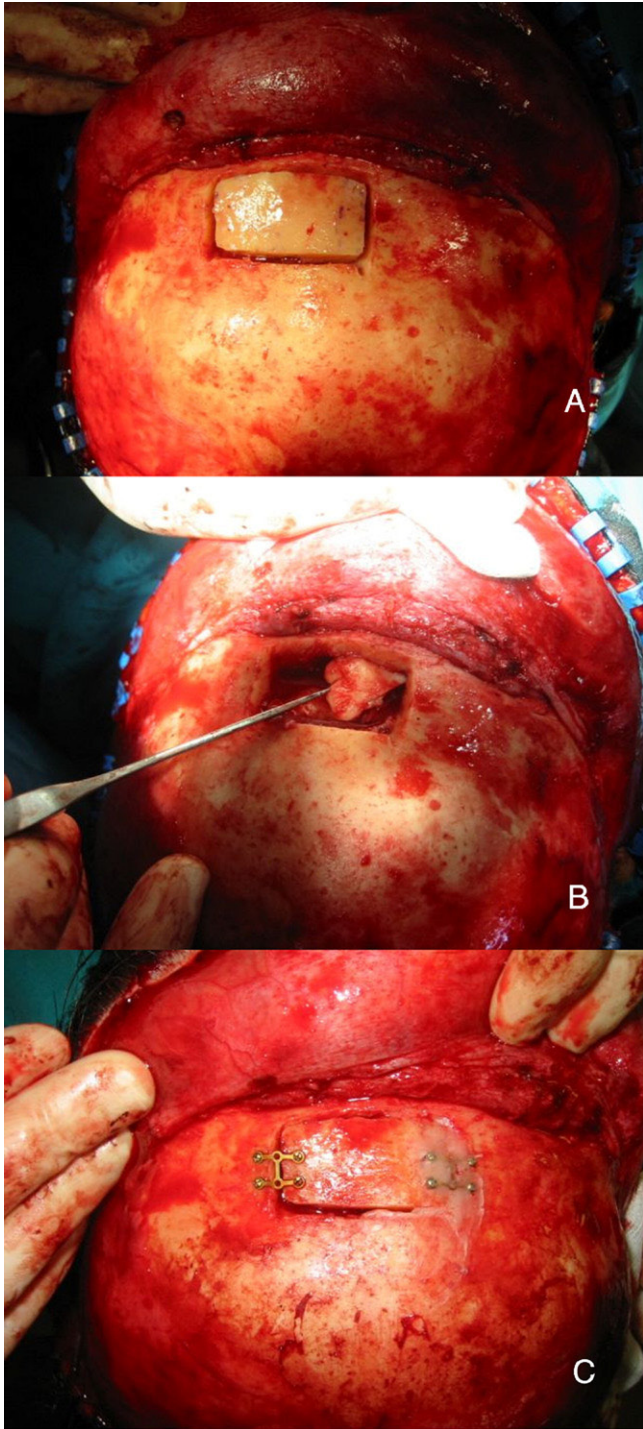


Fig. 2. Intraoperative images. (A) A rectangle of frontal bone was cut with a Lindemann burr. (B) The osteoma was removed by the combined use of a round burr and a chisel. (C) The frontal bony fragment was fixed with 2 H-shaped titanium miniplates. The gap between the reassembled fragment and the frontal bone was sealed with bony wax.

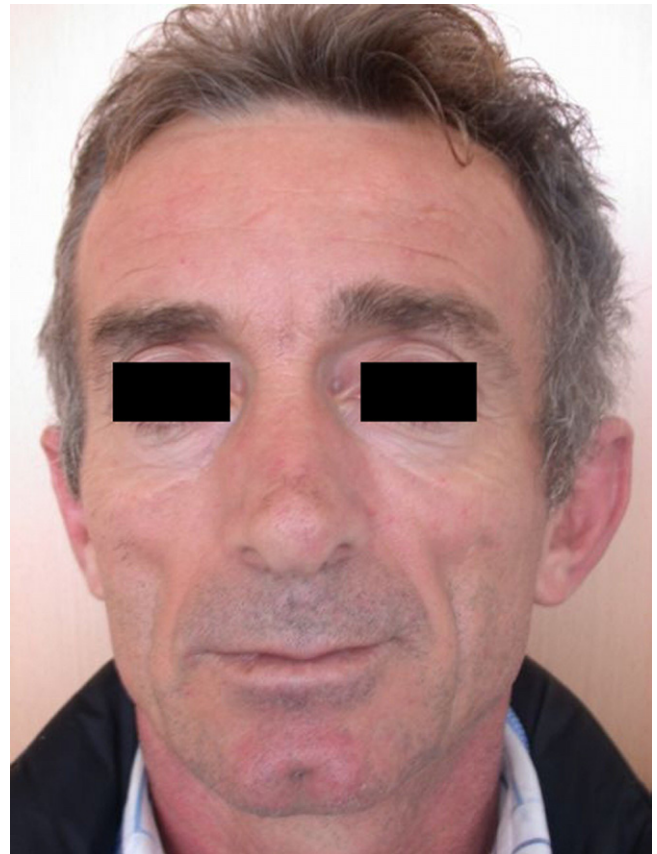

Fig. 3. Excellent aesthetic result at 11-month follow-up control.

nasal septum, paranasal sinus opacity, and an inflammatory pseudocyst on the right maxillary sinus with no bone erosion; the presence of a 30-mm lesion in the medial region of the frontal sinus, radiologically consistent with an osteoma, was shown (Fig. 1).

Because of the localization and size of the tumor and the age of the patient, we decided to use the bicoronal approach to avoid unaesthetic scars and to obtain a radical excision of the tumor. Under general anesthesia, after local injection of lidocaine with epinephrine, we performed a bicoronal incision according to Unterberger, a subgaleal flap up to the superior orbital rim, and an inverted U-shaped incision of the frontal periosteum. According to CT scan, a rectangle of frontal bone was cut with a Lindemann burr, keeping a 45° degree inclination to be able to remove it without any damage (Fig. 2A). The bone fragment was preplated by means of 2 titanium plates (1.3 mm), then the frontal segment was removed with a small chisel. The osteoma had to be split into 2 parts because of its considerable dimension (30 × 30 × 15 mm) so that it could be removed completely while preserving the surrounding bone. The osteoma was removed with a round burr and a chisel; the round burr was also used to remove the mucosal lining of the frontal sinus (Fig. 2B). The frontal bony fragment that was removed was set back in place and fixed with the 2 H-shaped, preplated

titanium plates. The gap between the reassembled fragment and the frontal bone was sealed with bony wax (Fig. 2C). The frontal periosteum was set back in place and the coronal flap was sutured by layers.

A postoperative CT scan of the skull confirmed the radical excision of the tumor. The postoperative course was regular. On the 10th postoperative day, all stitches were removed. Serial clinical evaluation every 15 days for 3 months and then once a month for 3 months were planned. The patient did not have periorbital headache and the aesthetic result was excellent (Fig. 3). At 21-month follow-up CT, there was no evidence of osteoma recurrence.

3. Discussion

Three types of surgical approaches have been described for the treatment of frontal sinus osteoma: the supraciliar, the endonasal, and the bicoronal. The choice of the operative approach and extent of the osteotomy depend on the dimension of the neoplasm, its relation with the anterior and posterior walls of the frontal sinus, and the dimensions of the sinus. Detailed CT examination can provide precise information about the origin, dimension, and localization of frontal osteoma; skull CT (axial and coronal views) is mandatory for surgical planning.

The supraciliar approach is usually chosen in bald patients or those with little hair and in patients with small sinuses or small osteomas located at the anterior wall of the frontal sinus. The supraciliar approach may not give good aesthetic results and recurrence rates are relatively high. The indications for endoscopic endonasal approach are limited to small osteomas of the posterior wall of the frontal sinus located close to the infundibulum [9]. The reported postoperative complications of this approach have been ptosis, diplopia, supraorbital anesthesia, and rhinoliqoral fistula.

From the available literature, the surgical technique with lower recurrence rate and better aesthetic results seems to be the bicoronal approach. The indications for bicoronal approach are frontal osteomas located at the anterior wall or laterally, very large tumors in large frontal sinuses, and patients with good hair growth [9,10]. Complications of the above-mentioned surgical technique, such as numbness, frontal branch (cranial nerve VII) weakness, dural damage with cerebrospinal fluid leakage, and damage of the orbital contents or intracranial structures, are quite unusual and have seldom been reported [11]. Although the bicoronal approach seems to give good functional and aesthetic results, only a few reports describe this technique in frontal osteoma treatment.

In frontal osteoma, careful evaluation of the location and dimension of the tumor, its relation with the anterior and posterior walls of the sinus, the dimension of the sinus, the patency of the rhinofrontal duct, the possible complications, and the risk of cosmetic deformity is mandatory for the choice of the surgical technique. In our case, choice of the bicoronal approach was made after carefully evaluating the location and the dimension of the tumor and the good hair growth of the patient. We avoided the classic frontal-ethmoid approach, which does not provide an adequate opening of the operative field and therefore does not allow complete excision of large osteomas. Moreover, high recurrence rates have been described with this technique, and good aesthetic results were not obtained. Our patient's osteoma was too large to consider an endonasal endoscopic approach.

For large osteomas of the frontal sinus, as in the case described above, the bicoronal approach is recommended. This approach provides an excellent surgical exposure, allowing the complete excision of the neoplasm, limiting the intra- and postoperative complications, reducing the recurrence rates, and giving an ideal aesthetic result.

References

- [1] Schwartz MS, Crockett DM. Management of a large frontoethmoid osteoma with sinus cranialization and cranial bone graft reconstruction. *Int J Pediatr Otorhinolaryngol* 1990;20:63-72.
- [2] Namdar I, Edelstein DR, Huo J, et al. Management of osteomas of the paranasal sinuses. *Am J Rhinol* 1998;12:393-8.
- [3] Fobe LP, Melo EC, Cannone LF, et al. Surgery of frontal sinus osteoma. *Arq Neuropsiquiatr* 2002;60:101-5.
- [4] Dispenza C, Saraniti C, Ferrara S, et al. Frontal sinus osteoma and palpebral abscess: case report. *Rev Laryngol Otol Rhinol* 2005;126:49-51.
- [5] Earwaker J. Paranasal sinus osteomas: a review of 46 cases. *Skeletal Radiol* 1993;22:417-23.
- [6] Gezici AR, Okay O, Ergun R, et al. Rare intracranial manifestations of frontal osteomas. *Acta Neurochir* 2004;146:393-6.
- [7] Bertran Mendizabal JM, Perez Martinez C, Martinez Vidal A. Osteoplastic frontal sinus flap. Study of 47 cases. *Acta Otorrinolaringol Esp* 1998;49:380-4.
- [8] Detsouli M, Laraqui NZ, Benghalem A, et al. Osteoma of the frontal sinus. Apropos of 10 cases. *Ann Otolaryngol Chir Cervicofac* 1995;112:293-7.
- [9] Weber R, Draf W, Constantinidis J, et al. Current aspects of frontal sinus surgery. IV: On therapy of frontal sinus osteoma. *HNO* 1995;43:482-6.
- [10] Chang SC, Chen PK, Chen YR, et al. Treatment of frontal sinus osteoma using a craniofacial approach. *Ann Plast Surg* 1997;38:455-9.
- [11] Blitzer A, Post KD, Conley J. Craniofacial resection of ossifying fibromas and osteomas of sinuses. *Arch Otolaryngol Head Neck Surg* 1989;115:1112-5.