
Arthrocentesis of the temporomandibular joint: a proposal for a single-needle technique

Luca Guarda-Nardini, MD, DDS,^a Daniele Manfredini, DDS,^b Giuseppe Ferronato, MD, DDS,^c
Padova, Italy
UNIVERSITY OF PADOVA

Arthrocentesis is a method of flushing out the temporomandibular joint (TMJ) that is currently performed by providing a double access to the joint space. Several studies have shown that arthrocentesis of the upper compartment of the TMJ may be a highly effective method to restore normal maximal mouth opening and functioning. Nonetheless, the classical 2-needle technique has some limits, such as the low tolerability and difficulty in performing it in the presence of intra-articular adhesions. The adoption of a single-needle for both fluid injection and aspiration might have some advantages with respect to the traditional 2-needle approach in terms of time of execution, tolerability, and retention of medication. These potential advantages have to be assessed with future randomized and controlled clinical trials. (*Oral Surg Oral Med Oral Pathol Oral Radiol Endod* 2008;106:483-6)

Arthrocentesis is a method of flushing out the temporomandibular joint (TMJ) by placing needles into the upper joint compartment using local anaesthesia or sedation.¹⁻⁷ According to the most common procedure, Ringer's lactate or physiological saline is injected into the joint by the use of a needle introduced into the superior joint space after local anesthetic infiltration of the overlying skin.⁸ This compartment will take up to 5 mL of fluid and, by filling under pressure, any minor adhesions are broken down or lysed. A second needle is then placed into the same joint compartment to achieve throughflow of fluid and to allow thorough washing or lavage of the joint.

The process is referred to as "lysis and lavage" and can produce good therapeutic outcomes, as reported in case series of patients with restricted mouth opening, due to either an anchored disk phenomenon or a non-reducing disk displacement.²⁻⁶ The effectiveness of joint lavage in those cases may be explained by the joint space expansion achieved with the introduction of fluid and by the washing out of inflammatory mediators and catabolytes. On the basis of observations suggesting that increased joint friction and reduced joint lubrication are involved in the process of disk displacement,^{9,10} a combined technique providing the injection

of hyaluronic acid at the end of the procedure to improve joint lubrication was proposed.¹¹⁻¹⁶

The improvement in the quality of joint environment achieved with the lavage seems to be the basis for an explanation of the efficacy of arthrocentesis in the treatment of restricted mouth opening. The available literature data contain information about indications, success rates, prognostic risk factors, and complication rates, suggesting that patients with TMJ osteoarthritis did not respond as well as the other groups of temporomandibular disorder (TMD) patients.

With the proposal and introduction of hyaluronic acid injection after arthrocentesis to restore joint lubrication, the indications for such technique were expected to extend to other TMJ disorders, and encouraging findings were reported in patients with inflammatory-degenerative disorders¹⁵⁻¹⁷ as well as internal derangements.¹¹⁻¹³ Thanks to its efficacy and minimal invasiveness, arthrocentesis has rapidly gained popularity in both research and clinical settings.

TWO-NEEDLE ARTHROCENTESIS

The currently adopted technique to perform arthrocentesis of the TMJ provides a double access to the joint space. Such an access is performed by taking as indicator the Holmlund line (Fig. 1), and consists of the positioning of two 19-G needles within a small virtual cavity (Fig. 2).

The articular lavage should be ideally performed in a single session through the injection of 300 mL of Ringer lactate solution or physiological saline, which appears to be the needed amount of fluid to remove all joint catabolytes.¹⁸

The classical 2-needle technique is easily applicable in the case of osteoarthritic joints with or without disk

^aDirector, TMD Clinic, University of Padova, Italy.

^bVisiting Professor, TMD Clinic, University of Padova, Italy.

^cFull Professor and Head, Department of Maxillofacial Surgery, University of Padova, Italy.

Received for publication April 27, 2007; returned for revision November 30, 2007; accepted for publication December 6, 2007.

1079-2104/\$ - see front matter

© 2008 Mosby, Inc. All rights reserved.

doi:10.1016/j.tripleo.2007.12.006

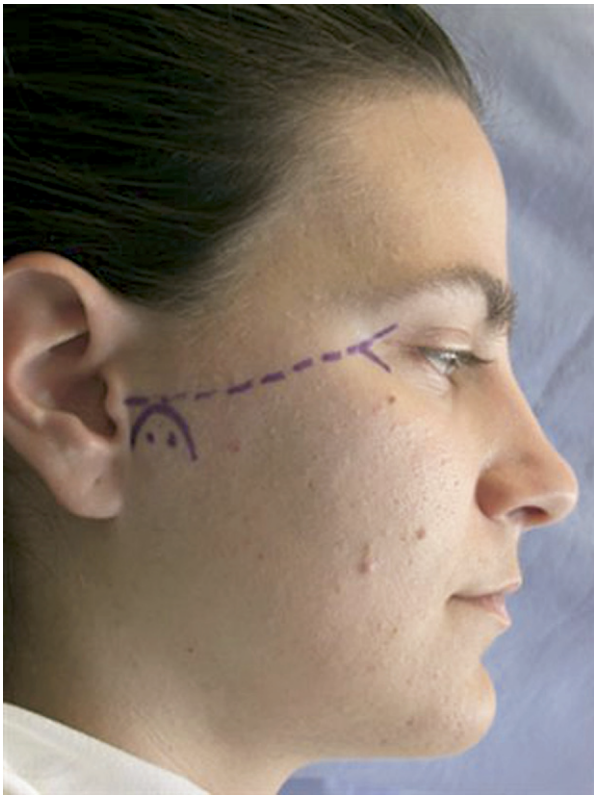


Fig. 1. Holmlund line and reference points for the two-needle technique.

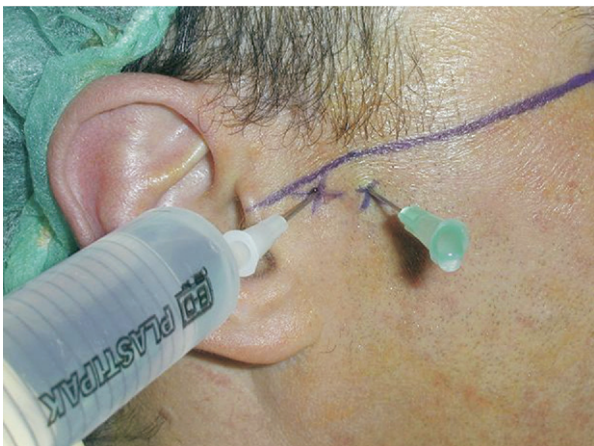

Fig. 2. Two-needle arthrocentesis.

displacement in the absence of fibrous adhesences, while it is more difficult to perform in the presence of intra-articular adhesences. Furthermore, even though tolerability is improved with respect to arthroscopy, the positioning of 2 needles within a small cavity like the TMJ may cause some discomfort to patients, particularly at the time of the first lavage. A study evaluating

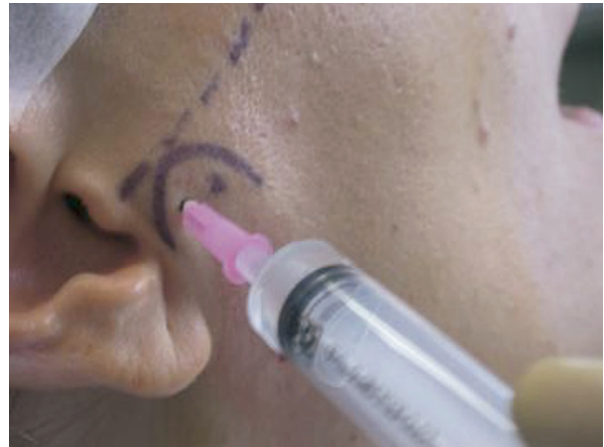

Fig. 3. Single-needle arthrocentesis.

the efficacy and tolerability of a cycle of 5 weekly hyaluronic acid injections performed after a classical 2-needle arthrocentesis showed that the patients' perception of tolerability increased with time (i.e., the last interventions were better tolerated than the first ones).¹⁶ Such findings were explainable with the progressive breakage of adhesions and removal of catabolytes achieved with the sequence of interventions, which made the insertion of the needles easier and, consequently, improved the quality of the posttreatment course.

PROPOSAL FOR A SINGLE-NEEDLE TECHNIQUE

A possible suggestion to improve the tolerability of TMJ arthrocentesis may be the introduction of a modified approach that provides the execution of a single-needle technique (Figs. 3 and 4). The use of a single needle for both fluid injection and aspiration might have some advantages with respect to the traditional 2-needle approach, the first of which being a reduced time of execution.

The positioning of a single needle should allow a surer and stable access to the joint space, while the positioning of a second needle might interfere with the stability of the first one.

The use of a single and more stable needle should limit the traumatism of the intervention, so reducing patients' pain and disability in the postoperative phase. The lower levels of postoperative discomfort are also due to the needed amount of anesthetic, which is lower in the single-needle approach.

This aspect becomes even more important when considering the risks of postoperative facial nerve paresthesia, which is a possible adverse reaction to the traditional 2-needle arthrocentesis. The need for a

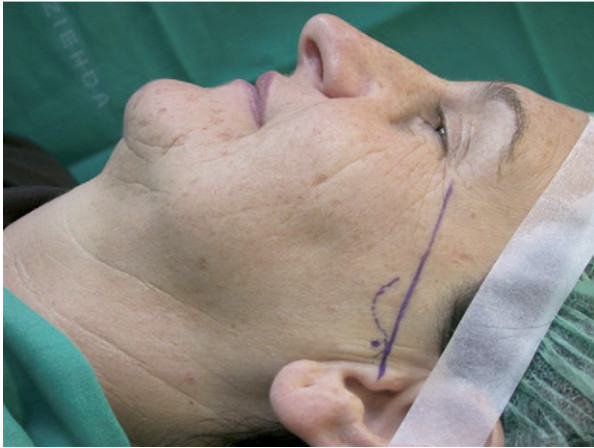

Fig. 4. Reference point for the single-needle technique.

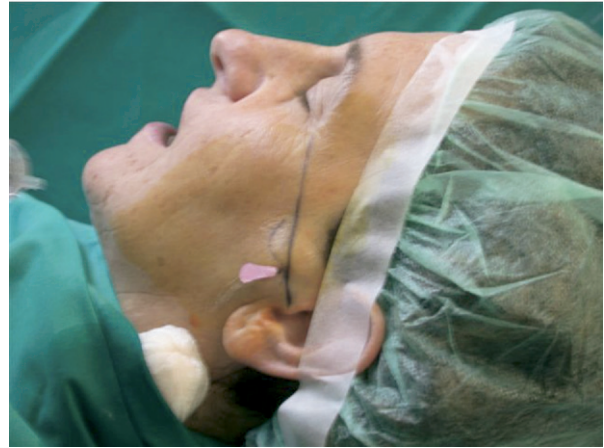

Fig. 6. The fluids get off the same injection needle.

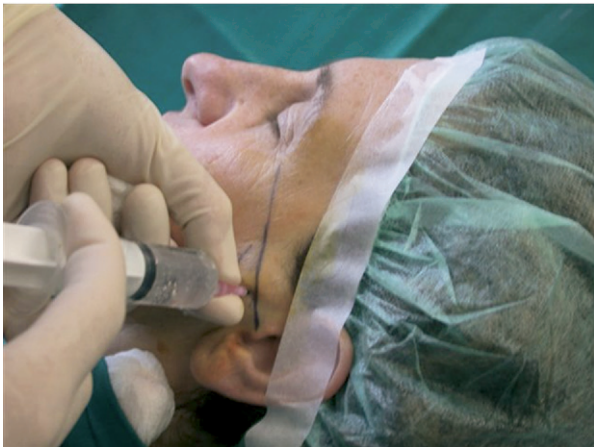

Fig. 5. Under pressure physiological saline injection.

lower amount of anesthetic should reduce the risks for an involvement of the facial nerve. Moreover, the insertion of a single needle should reduce the risks for nervous injuries as well, since an anteriorly positioned second needle may cause trauma to the facial nerve, which lays anteriorly and medially to the glenoid fossa, which is where the second needle is usually inserted.

The single-needle technique provides the under-pressure fluid injection with the patient in a mouth-open position, in order to expand the joint cavity (Fig. 5); after the injection, the patient is asked to close the mouth and the fluid is taken off with the same injection needle (Fig. 6). The injection-ejection process must be performed for up to 10 repetitions (for a total amount of about 40 ml).

The under-pressure injection of fluid is mostly useful to break joint adhesences that are responsible

for the reduced translatory movement of the condyle and are mainly called into cause to explain the phenomena of disk anchorage to the fossa and/or eminence, thus allowing an immediate improvement in mouth opening.^{2,19} This makes the single-needle technique indicated in the case of hypomobile joints with strong adhesences or joints with degenerative changes that make the insertion of the second needle difficult.

Moreover, additional advantages may be obtained with the adoption of a single-needle technique to perform arthrocentesis before the injection of hyaluronic acid, since the risk of hyaluronic acid flowing out through the second point of injection is absent. Therefore, a single-needle technique might allow full retention of the injected hyaluronic acid within the joint compartment.

The use of a single-needle technique has shown promising results in the clinical setting, and future trials will be addressed to compare findings of this newly proposed protocol with those of the traditional 2-needle technique.

CONCLUSIONS

The adoption of a single-needle injection technique might have some advantages over the traditional 2-needle technique. The following advantages will need to be assessed by means of well-designed clinical trials:

- A more sure and stable access to the joint space (the positioning of a second needle could interfere with the stability of the first one);
- A strong limitation of trauma due to the positioning of a second needle;
- A reduction in patients' postoperative pain and discomfort;

- A decrease in risks for side and adverse effects;
- A reduction in the execution time.

REFERENCES

1. Murakami KI, Iizuka T, Matsuki M, Ono T. Recapturing the persistent anteriorly displaced disk by mandibular manipulation after pumping and hydraulic pressure to the upper joint cavity of the temporomandibular joint. *J Craniomandib Pract* 1987;5:17-24.
2. Nitzan DW, Etsion I. Adhesive force: the underlying cause of the disc anchorage to the fossa and/or eminence in the temporomandibular joint—A new concept. *Int J Oral Maxillofac Surg* 2002;31:94-9.
3. Nitzan DW, Samson B, Better H. Long term outcome of arthrocentesis for sudden-onset, persistent, severe closed lock in the TMJ. *J Oral Maxillofac Surg* 1997;55:151-5.
4. Murakami K, Hosaka H, Moriya Y, Segami N, Iizuka T. Short-term treatment outcome study for the management of temporomandibular joint closed lock. A comparison of arthrocentesis to nonsurgical therapy and arthroscopic lysis and lavage. *Oral Surg Oral Med Oral Pathol Oral Radiol Endod* 1995;80:253-7.
5. Dimitroulis G, Dolwick MF, Martinez A. Temporomandibular joint arthrocentesis and lavage for the treatment of closed lock: a follow-up study. *Br J Oral Maxillofac Surg* 1995;33:23-6.
6. Hosaka H, Murakami K, Goto K, Iizuka T. Outcome of arthrocentesis for temporomandibular joint with closed lock at 3 years follow-up. *Oral Surg Oral Med Oral Pathol Oral Radiol Endod* 1996;82:501-4.
7. Fridrich KL, Wise JM, Zeitler DL. Prospective comparison of arthroscopy and arthrocentesis for temporomandibular joint disorders. *J Oral Maxillofac Surg* 1996;54:816-20.
8. Sanromán JF. Closed lock (MRI fixed disc): a comparison of arthrocentesis and arthroscopy. *Int J Oral Maxillofac Surg* 2004;33:344-8.
9. Nitzan DW. The process of lubrication impairment and its involvement in temporomandibular joint disc displacement: a theoretical concept. *J Oral Maxillofac Surg* 2001;59:36-45.
10. Nitzan DW, Kreiner B, Zeltser B. TMJ lubrication system: its effect on the joint function, dysfunction, and treatment approach. *Compen Contin Educ Dent* 2004;25:437-4.
11. Sato S, Oguri S, Yamaguchi K, Kawamura H, Motegi K. Pumping injection of hyaluronic acid for patients with non-reducing disc displacement of the temporomandibular joint: two year follow-up. *J Craniomaxillofac Surg* 2001;29:89-93.
12. Hepguler S, Akkoc YS, Pehlivan M, Ozturk C, Celebi G, Saracoglu A, et al. The efficacy of intra-articular hyaluronic acid in patients with reducing displaced disc of the temporomandibular joint. *J Oral Rehabil* 2002;29:80-6.
13. Alpaslan GH, Alpaslan C. Efficacy of temporomandibular joint arthrocentesis with and without injection of hyaluronic acid in treatment of internal derangements. *J Oral Maxillofac Surg* 2001;59:613-8.
14. Cascone P, Fonzi Dagger L, Aboh IV. Hyaluronic acid's biomechanical stabilization function in the temporomandibular joint. *J Craniomandib Surg* 2002;13:751-4.
15. Guarda-Nardini L, Tito R, Staffieri A, Beltrame A. Treatment of patients with arthrosis of the temporomandibular joint by infiltration of hyaluronic acid: a preliminary study. *Eur Arch Otorhinolaryngol* 2002;259:279-84.
16. Guarda-Nardini L, Masiero S, Marioni G. Conservative treatment of temporomandibular joint osteoarthritis: intra-articular injection of hyaluronic acid. *J Oral Rehabil* 2005;32:729-34.
17. Guarda-Nardini L, Stifano M, Brombin C, Salmaso L, Manfredini D. A one-year case series of arthrocentesis with hyaluronic acid injections for temporomandibular joint osteoarthritis. *Oral Surg Oral Med Oral Pathol Oral Radiol Endod* 2007;103:e14-e22.
18. Kaneyama K, Segami N, Nishimura M, Sato S, Fujimura K, Yoshimura H. The ideal lavage volume for removing bradykinin, interleukin-6, and protein from the temporomandibular joint by arthrocentesis. *J Oral Maxillofac Surg* 2004;62:657-61.
19. Guarda-Nardini L, Tito R, Beltrame A. Treatment of temporomandibular joint closed lock using intrarticular injection of mepivacaine with immediate resolution durable in time (six months follow-up). *Minerva Stomatol* 2002;51:21-8.

Reprint requests:

Dr. Daniele Manfredini
Viale XX Settembre 298
54036 Marina di Carrara (MS)
Italy
daniele.manfredini@tin.it