

# Trichilemmal carcinoma of the lower eyelid in a oculocutaneous albino patient

TO THE EDITOR: Trichilemmal carcinoma (TLC) is a rare cutaneous adnexal neoplasm deriving from the outer root of the hair follicles. It represents the malignant counterpart of trichilemmoma and occurs as vegetating, often ulcerated or crusted nodule or plaque usually arising in the sun-exposed areas of the elderly population. Head, neck and dorsum of the hand are the most frequently involved sites.<sup>1</sup> Oculocutaneous albinism is characterized by the lack of enzyme tyrosinase, essential for the production of melanin. These patients are born with bluish eyes and white hair and skin, and they maintain these features when growing old. They show an increased risk of skin cancer, mainly squamous and basal cell carcinomas.<sup>2</sup> We describe the case of a 70-year-old oculocutaneous albino patient that presented with a firm 15x7 mm right lower eyelid nodule (Figure 1). The patient referred that this nodule arose three months before as a little papule and grew very quickly to the actual size. The patient was also affected by psoriasis. The anamnesis revealed an exaggerated sun exposure in the past: the patient worked outdoor as bricklayer in Africa for 30 years. The patient developed several basal and squamous cell carcinomas and his whole face was affected by severe actinic keratoses. We treated the patient with numerous surgical excisions for the tumours and with methyl aminolevulinate-photodynamic therapy for the severe field cancerization of his sun exposed areas. We decided to surgically remove the nodule and we repaired the minus with an advancement flap. Histologically the neoplasia is lobulated, follicle centred, focally in continuity with epidermis.

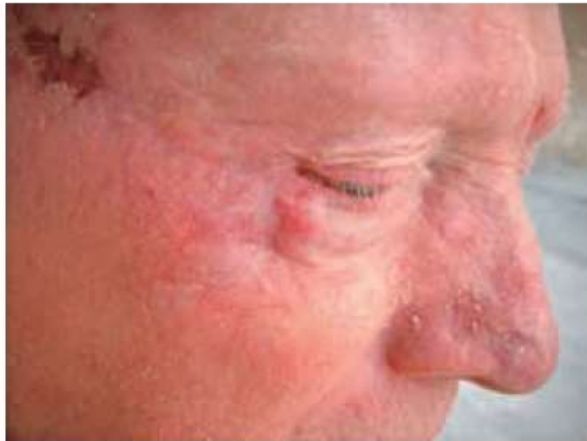

Figure 1.—Clinical aspect of the nodular lesion.

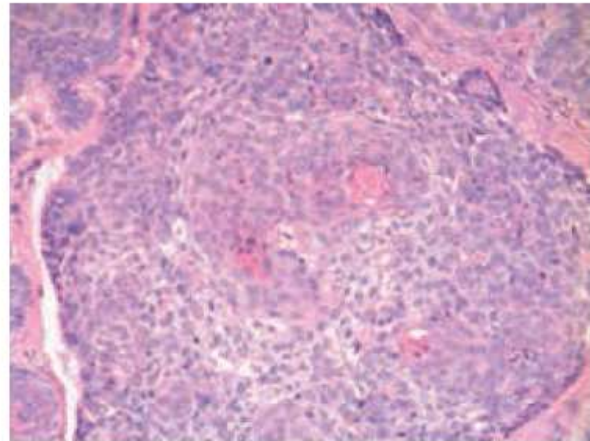


Figure 2.—Histological aspect of the lesion demonstrating a neoplasm composed of eosinophilic clear cell, peripheral nuclear palisading and trichilemmal keratinisation. Several mitotic figures are represented.

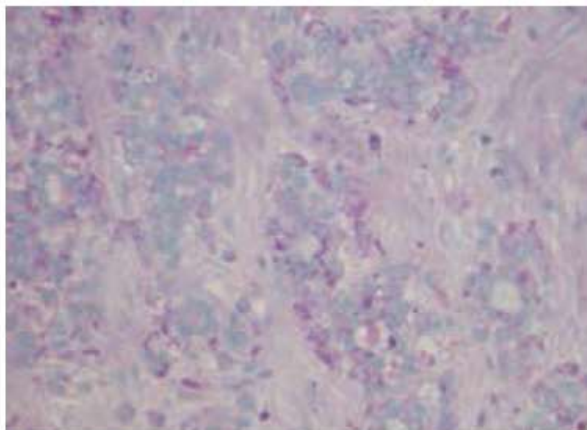


Figure 3.—Immunohistochemical PAS stain.

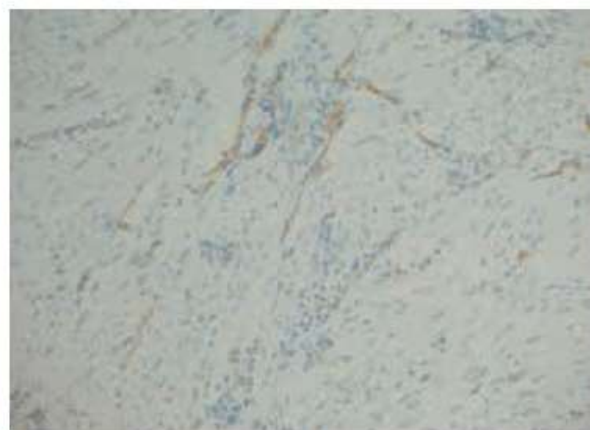

Figure 4.— Immunohistochemical CD34 stain.

It is composed of irregular nests and cords of eosinophilic cells with clear cytoplasm, high mitotic index, focal necrosis, picnosis and with invasive aspect involving the adjacent dermis irregularly with surrounding chronic inflammation and desmoplasia. Some of the tumor cells usually have PAS positive and diastase labile clear cytoplasm. Peripheral nuclear palisading is frequent at the periphery of the neoplastic lobules. Areas of trichilemmal keratinisation are disposed irregularly throughout the neoplasm which resembles squamous carcinoma.

Perineural infiltration is also frequent (Figure 2). TLC is a rare cutaneous adnexal neoplasm usually occurring in the sun-exposed areas of the elderly population; it originates from the external root sheath of the hair follicle<sup>3</sup> and can be considered a malignant variant of trichilemmoma. The pathogenesis of TLC involves actinic damage,<sup>4</sup> low dose, transformation from benign trichilemmoma. This malignancy that can be seen in both immunocompetent and immunosuppressed hosts. The clinical appearance resembles basal cell carcinoma, squamous cell carcinoma, sebaceous carcinoma, keratoacanthoma and nodular melanoma and usually manifests as a single nodule measuring <2 cm. Histology reveals multiples intradermal lobules and trabeculae with a peripheral palisade of basaloid cells continuous with the epidermis. Tumoral cells present a cytoplasm rich with glycogen and The cell membrane is pas positive and well defined (Figure 3). In Figure 4 a immunohistochemical stain with CD34 (marker of differentiation from the outer hair sheath is provided. Usually a malignant appearance, characterized by cytological atipia and high mitotic index, gives the impression of a high-grade malignant neoplasm.

Trichilemmal keratinisation, defined as an abrupt keratinization without a granular layer, is a common finding in TLC. Another feature of TLC is the epidermal spread, with an abrupt or pagetoid interface with normal keratinocytic layer. Despite of cytological malignant appearance, TLC has an indolent clinical course and shows no tendency to metastatize. Due to his local aggressive growth and frequent local recurrences, the recommended treatment for TLC is a wide surgical excision. When available, Mohs micrographic surgery should be performed to ensure complete removal of the malignancy. Albinism is characterized by a reduction in melanin pigment biosynthesis. Six different genes have found to be involved in Albinism. The main enzymatic defect is the lack of tyrosinase, a key enzyme in melanin synthesis. This deficiency results in an increased sensitivity to ultraviolet (UV) radiation and to a predisposition to skin cancer. Albino patients are also affected by photophobia, myopia and other visual problems including nystagmus and strabismus. These problems are due to the lack of retinal pigment required for the normal development of the visual system. UV exposure in hypopigmented skin causes severe skin damage. Most of the lesions are localized in sun-exposed areas as face, ears, neck and shoulders and include sunburns, blisters, solar elastosis/keratosis, ephelides, lentiginosis, and superficial ulcers. As said before, our patient spent most of his life working outdoor in Africa, and can be compared to these patients. Squamous cell carcinoma is the most increased skin cancer in albino patients, followed by basal cell carcinoma.

<sup>5</sup> Although non-melanomatous skin cancers are more common in patients with albinism, pigmented lesions can be difficult to evaluate in this patients because of their hypopigmented appearance. Interestingly, the pattern of skin cancer incidence changes occurring in albino patients has similarities with the immunosuppressed population, although the mechanisms causing skin cancer's incidence increase are different.

To the best of our knowledge, this is the first case of TLC in a patient affected by oculocutaneous albino syndrome.

E. ZATTRA

*Unit of Dermatology, University of Padua, Padua, Italy*  
edoardo.zattra@unipd.it

L. GUARDA NARDINI

*Unit of Maxillar Surgery, University of Padua, Padua, Italy*

R. SALMASO

*Unit of Pathology, University of Padua, Padua, Italy*

S. PIASERICO

*Unit of Dermatology, University of Padua, Padua, Italy*

G ITAL DERMATOL VENEREOL 2014;150:131-3

## References

1. Reis JP, Tellechea O, Cunha MF, Baptista AP. Trichilemmal carcinoma: a review of eight cases. *J Cutan Pathol* 1993;20:44-9.
2. Oetting WS, King RA. Molecular basis of albinism: mutations and polymorphisms of pigmentation genes associated with albinism. *Hum Mutat* 1999;13:99-115.
3. Swanson PE, Marrogi AJ, Williams DJ, Chewitz DL, Wick MR. Trichilemmal carcinoma: clinicopathologic study of 10 cases. *J Cutan Pathol* 1992;19:100-9.
4. Misago N, Tanaka T, Kohda H. Trichilemmal carcinoma occurring in a lesion of solar keratosis. *J Dermatol* 1993;20:358-64
5. Freire-Maia N, Cavalli IJ. Albinism, skin carcinoma and chromosome aberrations. *Clin Genet*. 1980;17:46-7.