

Management of temporomandibular joint degenerative disorders with human amniotic membrane: Hypothesis of action



Luca Guarda-Nardini^a, Diletta Trojan^b, Adolfo Paolin^b, Daniele Manfredini^{c,*}

^aSection of Dentistry and Maxillofacial Surgery, Treviso Hospital, Treviso, Italy

^bTreviso Tissue Bank Foundation, Treviso, Italy

^cSchool of Dentistry, Department of Neuroscience, University of Padova, Padova, Italy

ARTICLE INFO

Article history:

Received 3 April 2017

Accepted 28 May 2017

ABSTRACT

Approaches providing the positioning of human amniotic membrane (HAM) within the intra-articular space of arthritic TMJs have never been investigated. This contrasts with the increasing amount of evidence suggesting the potential positive effects of HAM on a number of surgical conditions, even included the interpositional arthroplasty for TMJ ankylosis. Thus, the possible usefulness of HAM to restore joint functions in severely damaged TMJs could be hypothesized.

Based on these premises, the clinical research question “Is human amniotic membrane positioning effective to reduce symptoms and restore jaw function in patients with severe inflammatory-degenerative disorders of the temporomandibular joint?” has been addressed by performing a systematic review of the literature. Out of potential 11988 and 8883 citations in the PubMed and Scopus databases, respectively, only five were of possible interest for inclusion in the review, but none of them addressed specifically the clinical research question.

Thus, the hypothetical background for usefulness was discussed. The benefits of HAM positioning in TMJs with severe inflammatory-degenerative disorders could be related with its anti-inflammatory and anti-microbial and analgesic properties as well as its low immunogenicity. Studies in which HAM is positioned within the joint space of patients with severe TMJ degeneration, either as a disc-replacing film during major surgeries for discectomy and arthroplasty or as an injectable solution that can be needle-inserted after an arthrocentesis procedure, should be designed to test the hypothesis.

© 2017 Elsevier Ltd. All rights reserved.

Introduction

Temporomandibular Disorders (TMD) are a heterogeneous group of pathologies affecting the temporomandibular joint (TMJ), the jaw muscles, or both [1]. They are characterized by a classically described triad of clinical signs: muscle and/or TMJ pain; TMJ sounds; and restriction, deviation, or deflection of the mouth opening path. TMD are considered the most common orofacial pain conditions of non-dental origin, but the frequent concurrent presence of other symptoms, such as earache, headache, neuralgia, and tooth pain, which may be related to the TMD or be present as ancillary findings to be assessed in the differential diagnosis process, makes the assessment of TMD prevalence a complex issue [2].

The actual TMD prevalence at the population level is a matter of debate, due to the lack of homogeneity in the diagnostic criteria

adopted in the different investigations. There is evidence that the prevalence of TMD signs and symptoms may be high in the general population. Early investigations suggested that 1–75% of general population subjects showed at least one objective TMD sign, and that 5–33% reported subjective symptoms. TMD symptoms have been always considered to have a broad prevalence peak between 20 and 40 years of age, with a lower prevalence in younger and older people. For specific TMD conditions, distinct peaks were recently identified in patient populations, one around the age of 30 for subjects with disc displacements and one over the age of 50 for inflammatory-degenerative joint disorders [3].

Within this framework, degenerative disorders of the temporomandibular joint (TMJ) are thus becoming an increasingly frequent cause of orofacial pain, being diagnosed in about one-third (30.1%) of subjects belonging to patient populations [4]. Over the years, several approaches have been proposed to manage symptoms associated with such disorders and to improve joint function; among those, viscosupplementation with hyaluronic acid (HA) injections has been gaining diffusion [5]. Such strategy has been introduced within the practice of TMJ disorders as a consequence

* Corresponding author at: School of Dentistry, University of Padova, Via Giustiniani 2, 35100 Padova, Italy.

E-mail address: daniele.manfredini@tin.it (D. Manfredini).

of the progressive modification of TMJ arthrocentesis [6–8] as well as of the increasing knowledge about the potential application of hyaluronic acid to manage osteoarthritis (OA) of larger joints [9–11].

The potential role of joint lubrication impairment as a risk factor for TMJ internal derangements and the subsequent inflammatory-degenerative disorders has provided a rationale for TMJ viscosupplementation, and there is an amount of clinical evidence showing that it may be an effective treatment modality [12–17]. Since the time of their introduction in the field of TMJ disorders' practice, strategies to provide viscosupplementation to the TMJ joint have gone through a progressive expansion of their potential clinical indications, with particular regard to joints with inflammatory-degenerative disorders. Protocols for symptoms management in larger joints provided the adoption of a cycle of five weekly HA injections immediately, and encouraging findings soon emerged also from long-term case series on patients with TMJ disorders.

Contrarily, approaches providing the positioning of human amniotic membrane (HAM) within the intra-articular space of arthritic TMJs have never been investigated. This contrasts with the increasing amount of evidence suggesting the potential positive effects of HAM on a number of surgical conditions, even included the interpositional arthroplasty for TMJ ankylosis [18,19]. Thus, the possible usefulness of HAM to restore joint functions in severely damaged TMJs could be hypothesized.

Based on these premises, the clinical research question "Is human amniotic membrane positioning effective to reduce symptoms and restore jaw function in patients with severe inflammatory-degenerative disorders of the temporomandibular joint?" has been addressed by performing a systematic review of the literature and discussing the hypothetical background for usefulness.

Evaluation of the idea

Evidence

As a first step, a systematic search in PubMed, Scopus, Web of Science, SciELO, and Google Scholar databases was performed on March 13, 2017, combining the MeSh and keyword terms (amniotic membrane) AND (temporomandibular joint). No time, language, or article type limits were set. Five manuscripts were found.

As a second step, the literature search was extended to the full citation lists identified by the term "amniotic membrane" in the above databases. In addition, the search was also expanded to the related article lists and to the authors' personal collections. An author (DT) screened the abstracts of the full list of citations to identify potential articles for full-text retrieval. Any decision about the inclusion/exclusion in the review was made by consensus with the two supervisors (LGN; DM).

Empirical data

The first search step did not identify any citation pertinent to the potential use of amniotic membrane to manage inflammatory-degenerative TMJ disorders. Thus, the search was extended to the full citation lists identified by the term "amniotic membrane" alone, which provided 11988 and 8883 citations in the PubMed and Scopus databases, respectively. Examination of the titles and abstracts (TiAb) led to the exclusion of all papers: none had a study design specifically aimed at addressing the clinical research question or discussing its potential plausibility. As a general remark, only two articles dealing with preliminary data on the positioning of HAM during interventions on TMJ ankylosis [18,19],

two experimental articles on its effects in rabbits' TMJs [20,21], and an article reviewing the available knowledge on the possible developments in the field of oral and maxillofacial surgery [22] were of potential interest, but none of them addressed specifically the clinical research question. Therefore, all articles were excluded.

Thus, because of the absence of relevant literature on the topic, a background for the hypothesis of HAM effectiveness in TMJs with severe inflammatory-degenerative disorders is provided below.

The hypothesis

The amniotic membrane is the inner layer of the fetal membranes and is comprised of three distinct layers; epithelium, basement membrane and stroma, the inner most layer that further consists of an inner compact layer, middle fibroblast layer and an outermost spongy layer.

HAM has been used in a variety of surgical procedures. First employed in skin transplantation by in the early decades of past century [23], it was subsequently found to be useful as a biological wound dressing for burns [24,25], acute [26] and chronic wounds [27,28], and in the reconstruction of the dura mater [29,30], oral cavity [31], vaginal vault [32], tendons [33] and nerves [34]. Currently, HAM is also widely used for ocular surface reconstruction and treatment of several important ocular diseases [35] such as cicatricial pemphigoid, Stevens–Johnson syndrome [36], pterygium [37], persistent epithelial defects with ulceration [38], conjunctival and ocular surface reconstruction [39,40].

The benefits of HAM positioning in TMJs with severe inflammatory-degenerative disorders could be related with its anti-inflammatory and anti-microbial properties [41] and low immunogenicity [42,43]. In addition, thanks to its analgesic properties, it has been demonstrated that the application of HAM to wounds markedly reduces patients' experienced pain intensity [44].

Future studies

Future studies should be performed to test the above hypothesis. The preparation of HAM for its positioning within the joint is an important procedure to standardize.

Selection criteria for donors include absence of history of malignancies, absence of malformations or pathological conditions of the baby, gestation period of at least 35 weeks, negative familiarity for genetic diseases, and lifestyles of both parents not at risk for infectious diseases. The donor is also screened during pregnancy for neurodegenerative diseases and acute infections as well as for blood Human Immunodeficiency Virus (HIV) 1 and -2 antibodies, HTLV-1 and -2 antibodies, Hepatitis B (HBV) Surface Antigen and Core Antibody, Hepatitis C (HCV) virus antibodies and syphilis. Screening should also include IgM/IgG antibodies against Toxoplasmosis and Cytomegalovirus and nucleic acid amplification tests (NAT) for HIV, HBV and HCV.

The placenta is usually sourced from donors undergoing caesarean sections and processed shortly after retrieval. The HAM is carefully detached from the chorion and rinsed with sterile saline solution to remove residual blood. The membrane is flattened on a nitrocellulose membrane filter (Merck Millipore), with its stromal/mesenchymal side facing down, in contact with the filter. The HAM should be immersed in a cocktail of antibiotics including vancomycin 100 µg/ml (Hospira), meropenem 200 µg/ml (Frese-nius Kabi Italia), gentamicin 200 mg/ml (Fisiopharma) at +4 °C for 24 h in sterile conditions, validated for human tissues [45]. HAM then undergoes freeze-drying process in order to obtain injectable end products.

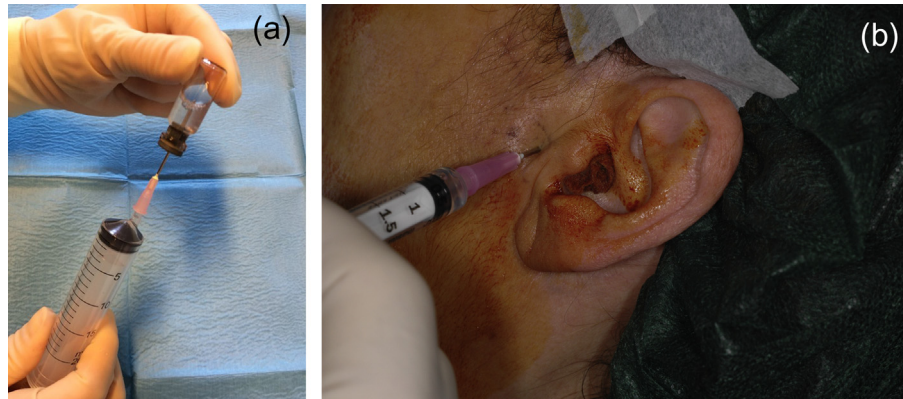


Fig. 2. HAM preparation (a) for intrarticular positioning after joint lavage with single-needle arthrocentesis (b).

It has been shown that freeze-drying process does not affect the properties of HAM, both in terms of cytokines and growth factors concentrations and biological ultrastructure, whereas the γ -irradiation process performed after freeze-dried process leads to a significant decrease in the tissue inhibitors of metalloproteinase-4, basic fibroblast growth factor and epidermal growth factor, and induces structural damage to the epithelium, basement membrane and lamina densa. The higher the irradiation dose the more severe the damage to the HAM [46].

Microbiological analyses are performed at several stages throughout the process and only HAMs without microbial contamination were considered suitable for implants.

The so-obtained product is positioned within the joint space of patients with severe TMJ degeneration, either as a disc-replacing film during major surgeries for discectomy and arthroplasty (Fig. 1) or as an injectable solution that can be needle-inserted after an arthrocentesis procedure (Fig. 2).

In the former condition, comparison should be made against existing disc-replacement materials, in line with current case series on the use of HAM in combination or instead of temporalis fascia for interpositional arthroplasty in patients with TMJ ankylosis [18,19]. As for joint lavage procedure, HAM preparations could be used as an alternative option to viscosupplementation following joint lavage. Comparison trials should be performed to assess the two techniques and test the potential of HAM as a joint tissue regeneration enhancer.

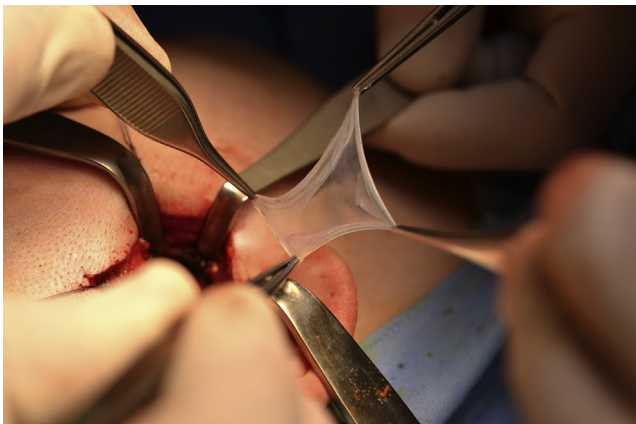


Fig. 1. HAM placement within the intrararticular gap during interpositional arthroplasty.

Consequences of the hypothesis

As a consequence of hypothesis testing, HAM placement within the temporomandibular joint space may find a rationale for use and a refinement of its indications. Several factors, including cost-to-benefit ratio as well as the predictability of TMJ arthrosis management within a biopsychosocial framework, should be considered for the possible introduction of HAM treatment within the armamentarium of the TMD practitioners.

Conclusions

The possible usefulness of HAM positioning within the intra-articular space of temporomandibular joints with severe inflammatory-degenerative disorders has never addressed in the literature. Based on the emerging indications of its possible analgesic and regenerative effects, the design of trials on the topic should be encouraged for its possible inclusion within the field of TMD practice.

Conflict of interest

No conflict of interest, financial or otherwise, is declared by the authors.

References

- [1] Dworkin S, LeResche L. Research diagnostic criteria for temporomandibular disorders: review, criteria examinations and specifications, critique. *J Craniomandib Disord Fac Oral Pain* 1992;6:301–55.
- [2] Peck CC, Goulet JP, Lobbezoo F, Schiffman EL, Alstergren P, Anderson GC, et al. Expanding the taxonomy of the diagnostic criteria for temporomandibular disorders. *J Oral Rehabil* 2014;41:2–23.
- [3] Manfredini D, Ahlberg J, Winocur E, Guarda-Nardini L, Lobbezoo F. Correlation of RDC/TMD axis I diagnoses and axis II pain-related disability. A multicenter study. *Clin Oral Invest* 2011;15:749–56.
- [4] Manfredini D, Guarda-Nardini L, Winocur E, Piccotti F, Ahlberg J, Lobbezoo F. Research diagnostic criteria for temporomandibular disorders. A systematic review of axis I epidemiological findings. *Oral Surg Oral Med Oral Pathol Oral Radiol Endod* 2011;112:453–62.
- [5] de Souza RF, Lovato da Silva CH, Nasser M, Fedorowicz Z, Al-Muharrraqi MA. Interventions for the management of temporomandibular joint osteoarthritis. *Cochrane Database Syst Rev* 2012;4:CD007261.
- [6] Nitzan DW, Dolwick MF, Martinez GA. Temporomandibular joint arthrocentesis: a simplified method for severe, limited mouth opening. *J Oral Maxillofac Surg* 1991;49:1163–7.
- [7] Nitzan DW. "Friction and adhesive forces": possible underlying causes for temporomandibular joint internal derangement. *Cells Tissues Organs* 2003;174:6–16.
- [8] Guarda-Nardini L, Ferronato G. TMJ arthrocentesis. In: Manfredini D, editor. *Current concepts on temporomandibular disorders*. Berlin: Quintessence Publishing; 2010. p. 393–402.
- [9] Ehrlich GE. Osteoarthritis. In: Raket BE, Bope ET, editors. *Conn's current therapy*. New York: Elsevier; 2006. p. 921.

- [10] Altman RD. Intra-articular sodium hyaluronate in osteoarthritis of the knee. *Semin Arthritis Rheum* 2000;30:11–8.
- [11] Pavelka K, Uebelhart D. Efficacy evaluation of highly purified intra-articular hyaluronic acid (Sinovial[®]) vs hylan G-F20 (Synvisc[®]) in the treatment of symptomatic knee osteoarthritis. A double-blind, controlled, randomized, parallel-group non-inferiority study. *Osteoarthritis Cartilage* 2011;19:1294–300.
- [12] Møystad A, Mork-Knutsen BB, Bjørnland T. Injection of sodium hyaluronate compared to a corticosteroid in the treatment of patients with temporomandibular joint osteoarthritis: a CT evaluation. *Oral Surg Oral Med Oral Pathol Oral Radiol Endod* 2008;105:e53–60.
- [13] Oliveras-Moreno JM, Hernandez-Pacheco E, Oliveras-Quintana T, Infante-Cossio P, Gutierrez-Perez JL. Efficacy and safety of sodium hyaluronate in the treatment of Wilkes stage II disease. *J Oral Maxillofac Surg* 2008;66:2243–6.
- [14] Guarda-Nardini L, Cadorní C, Frizziero A, Ferronato G, Manfredini D. Comparison of 2 hyaluronic acid drugs for the treatment of temporomandibular joint osteoarthritis. *J Oral Maxillofac Surg* 2012;70:2522–30.
- [15] Guarda-Nardini L, Ferronato G, Manfredini D. Two-needle vs. single-needle technique for TMJ arthrocentesis plus hyaluronic acid injections: a comparative trial over a six-month follow up. *Int J Oral Maxillofac Surg* 2012;41:506–13.
- [16] Manfredini D, Piccotti F, Guarda-Nardini L. Hyaluronic acid in the treatment of TMJ disorders. A systematic review of the literature. *Cranio* 2010;28:166–76.
- [17] Manfredini D, Rancitelli D, Ferronato G, Guarda-Nardini L. Arthrocentesis with or without additional drugs in temporomandibular joint inflammatory-degenerative disease: comparison of six treatment protocols*. *J Oral Rehabil* 2012;39:245–51.
- [18] Ahkter M, Ahmed N, Arefin MR, Sobhan M, Molla MR, Kamal M. Outcome of amniotic membrane as an interpositional arthroplasty of TMJ ankylosis. *Oral Maxillofac Surg* 2016;20:63–71.
- [19] Bauer F, Hingsammer LM, Wolff KD, Kesting MR. Temporomandibular joint arthroplasty with human amniotic membrane: a case report. *Eplasty* 2013;13:17.
- [20] Tuncel U, Ozgenel GY. Use of Human Amniotic Membrane as an interpositional material in treatment of temporomandibular joint ankylosis. *J Oral Maxillofac Surg* 2011;69:e58–66.
- [21] Tuncel U, Kostakoglu N, Turan A, Markoc F, Gokce E, Erkorkmaz U. Kesting. The use of temporalis muscle graft, fresh and cryopreserved amniotic membrane in preventing temporomandibular Joint ankylosis after discectomy in rabbits. *J Craniomaxillofac surg* 2014;42:1868–76.
- [22] Kesting MR, Wolff KD, Nobis CP, Rohleder NH. Amniotic membrane in oral and maxillofacial surgery. *Oral Maxillofac Surg* 2014;18:153–64.
- [23] Davis JW. Skin transplantation with a review of 550 cases at the Johns Hopkins Hospital. *Johns Hopkins Med J* 1910:15–307.
- [24] Branski LK, Herndon DN, Celis MM, Norbury WB, Masters OE, Jeschke MG. Amnion in the treatment of pediatric partial-thickness facial burns. *Burns* 2008;34(3):393–9.
- [25] Ramakrishnan KM, Jayaraman V. Management of partial-thickness burn wounds by amniotic membrane: a cost-effective treatment in developing countries. *Burns* 1977;23(Suppl 1):S33–6.
- [26] Tekin S, Tekin A, Kucukkartallar T, Cakir M, Kartal A. Use of chorioamniotic membrane instead of bogota bag in open abdomen: how I do it? *World J Gastroenterol* 2008;14(5):815–6.
- [27] Gajiwala K, Lobo Gajiwala A. Use of banked tissue in plastic surgery. *Cell Tissue Bank* 2003;4(2–4):141–6.
- [28] Insausti CL, Alcaraz A, García-Vizcaíno EM, Mrowiec A, López-Martínez MC, Blanquer M, et al. Amniotic membrane induces epithelialization in massive posttraumatic wounds. *Wound Repair Regen* 2010;18(4):368–77.
- [29] Tomita T, Hayashi N, Okabe M, Yoshida T, Hamada H, Endo S, et al. New dried human amniotic membrane is useful as a substitute for dural repair after skull base surgery. *J Neurol Surg B Skull Base* 2012;73(5):302–7.
- [30] de Weerd L, Weum S, Sjavik K, Acharya G, Hennig RO. A new approach in the repair of a myelomeningocele using amnion and a sensate perforator flap. *J Plast Reconstr Aesthet Surg* 2013;66(6):860–3.
- [31] Lawson VG. Oral cavity reconstruction using pectoralis major muscle and amnion. *Arch Otolaryngol* 1985;111(4):230–3.
- [32] Ashworth MF, Morton KE, Dewhurst J, Lilford RJ, Bates RG. Vaginoplasty using amnion. *Obstet Gynecol* 1986;67(3):443–6.
- [33] Ozbölük S, Ozkan Y, Oztürk A, Gül N, Ozdemir RM, Yanik K. The effects of human amnion membrane and periosteal autograft on tendon healing: experimental study in rabbits. *J Hand Surg Eur* 2010;35(4):262–8.
- [34] O'Neill AC, Randolph MA, Bujold KE, Kochevar IE, Redmond RW, Winograd JM. Preparation and integration of human amnion nerve conduits using a light activated technique. *Plast Reconstr Surg* 2009;124(2):428–37.
- [35] Paolin A, Cogliati E, Trojan D, Griffoni C, Grassetto A, Elbadawy HM, et al. Amniotic membranes in ophthalmology: long term data on transplantation outcomes. *Cell Tissue Bank* 2016;17(1):51–8.
- [36] Tsubota K, Satake Y, Ohyama M, Toda I, Takano Y, Ono M, et al. Surgical reconstruction of the ocular surface in advanced ocular cicatricial pemphigoid and Stevens-Johnson syndrome. *Am J Ophthalmol* 1996;122:38–52.
- [37] Prabhasawat P, Barton K, Burkett G, Tseng SCG. Comparison of conjunctival autografts, amniotic membrane grafts, and primary closure for pterygium excision. *Ophthalmology* 1997;104:974–85.
- [38] Lee SH, Tseng SCG. Amniotic membrane transplantation for persistent epithelial defects with ulceration. *Am J Ophthalmol* 1997;123:303–12.
- [39] Tseng SCG, Prabhasawat P, Lee S-H. Amniotic membrane transplantation for conjunctival surface reconstruction. *Am J Ophthalmol* 1997;124:765–74.
- [40] Shimazaki J, Yang H-Y, Tsubota K. Amniotic membrane transplantation for ocular surface reconstruction in patients with chemical and thermal burns. *Ophthalmology* 1997;104:2068–76.
- [41] Solomon A, Rosenblatt M, Monroy D, Ji Z, Pflugfelder SC, Tseng SCG. Suppression of interleukin 1 α and interleukin 1 β in human limbal epithelial cells cultured on the amniotic membrane stromal matrix. *Br J Ophthalmol* 2001;85:444–9.
- [42] Akle CA, Adinolfi M, Welsh KI, Leibowitz S, McColl I. Immunogenicity of human amniotic epithelial cells after transplantation into volunteers. *Lancet* 1981;318:1003–5.
- [43] Hori J, Wang M, Kamiya K, Takahashi H, Sakuragawa N. Immunological characteristics of amniotic epithelium. *Cornea* 2006;25:S53–8.
- [44] Mermet I, Pottier N, Sainthillier JM, Malugani C, CaireyRemonnay S, Maddens S, et al. Use of amniotic membrane transplantation in the treatment of venous leg ulcers. *Wound Repair Regen* 2007;15(4):459–64.
- [45] Serafini A, Riello E, Trojan D, Cogliati E, Palù G, Manganelli R, et al. Evaluation of new antibiotic cocktails against contaminating bacteria found in allograft tissues. *Cell Tissue Bank* 2016;17(4):619–28. Epub 2016 Sep 7.
- [46] Paolin A, Trojan D, Leonardi A, Mellone S, Volpe A, Orlandi A, et al. Cytokine expression and ultrastructural alterations in fresh-frozen, freeze-dried and γ -irradiated human amniotic membranes. *Cell Tissue Bank* 2016;17(3):399–406.