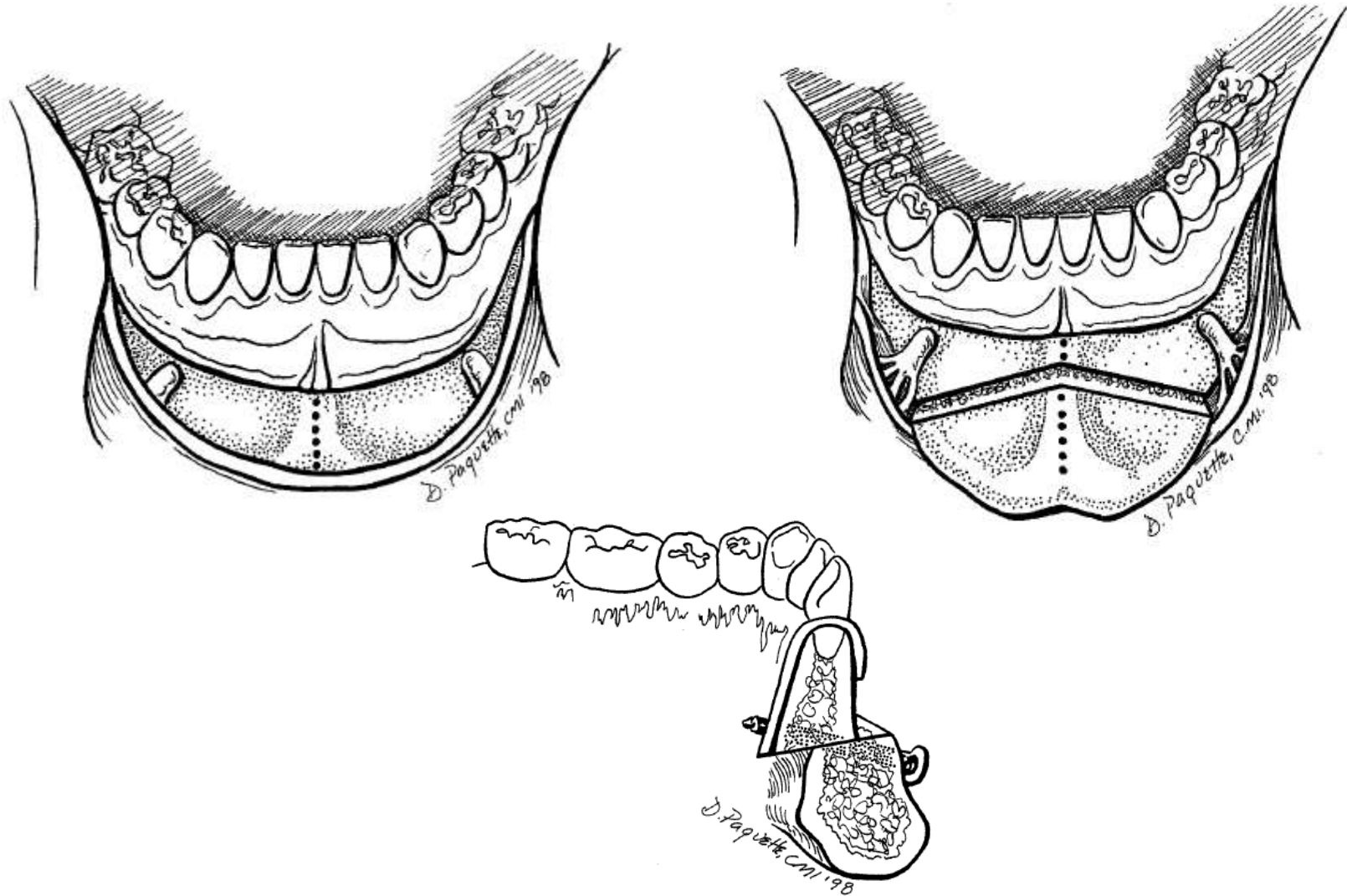


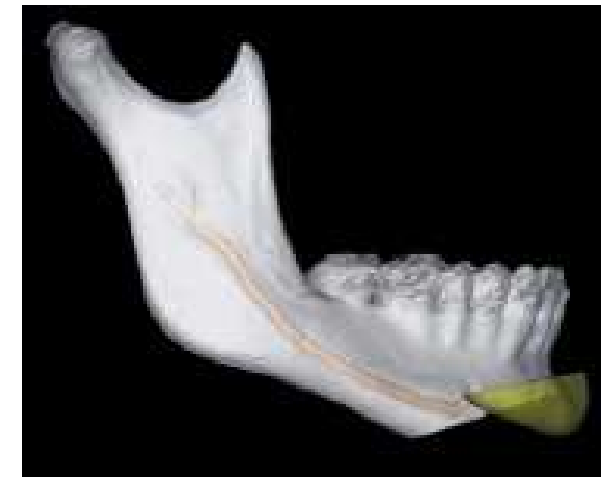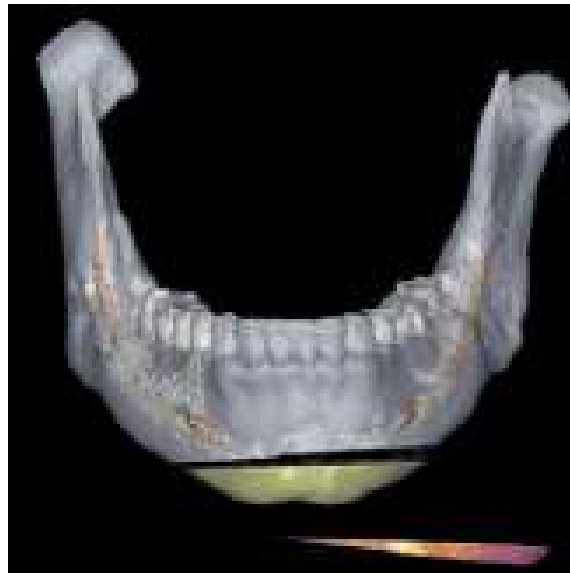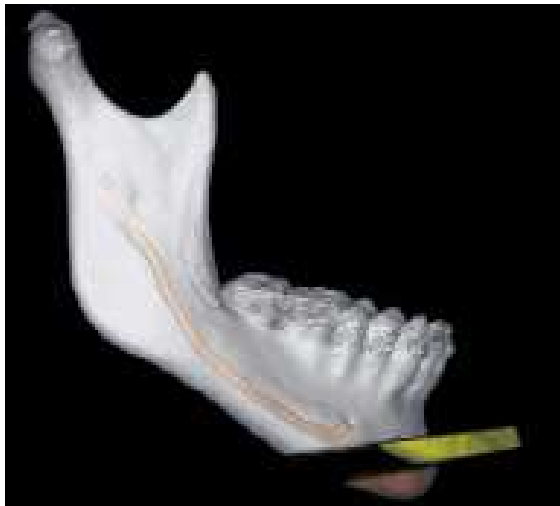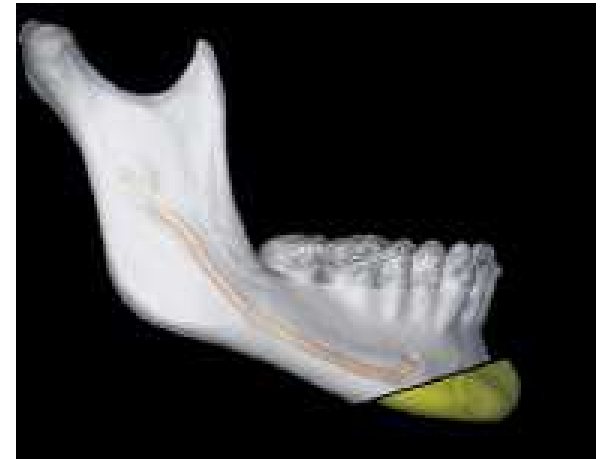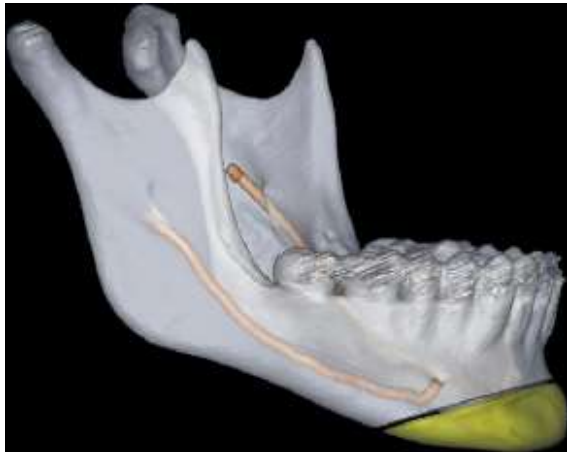
LA MENTOPLASTICA



LA MENTOPLASTICA

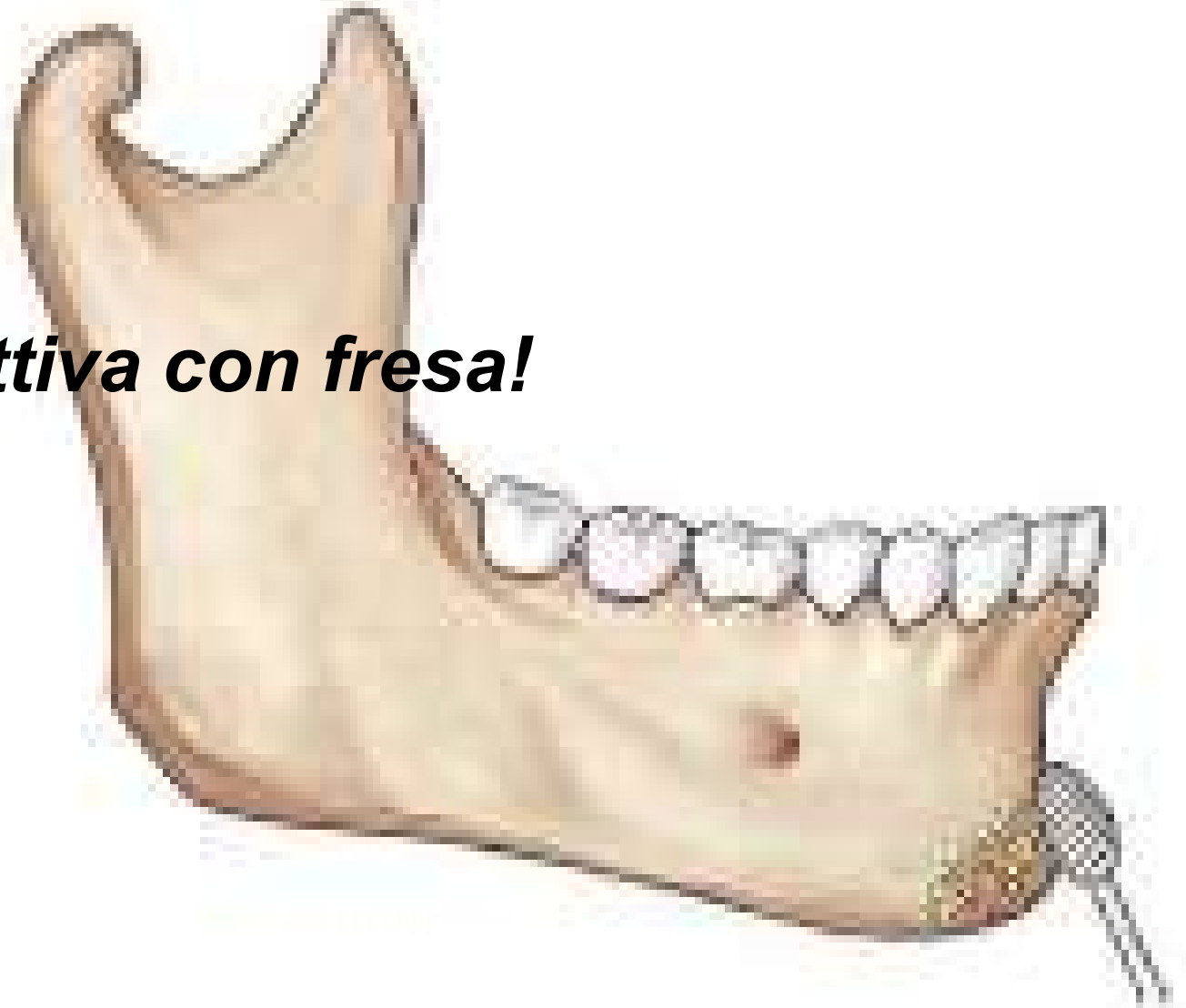- Hofer 1942
- Trauner e Obwegeser 1957
- Converse 1964
- Prinsell 1966 (OSAHS)
- Hohl e Epker 1976
- Mc Bride e Bell 1980.....
- Materiali eterologhi

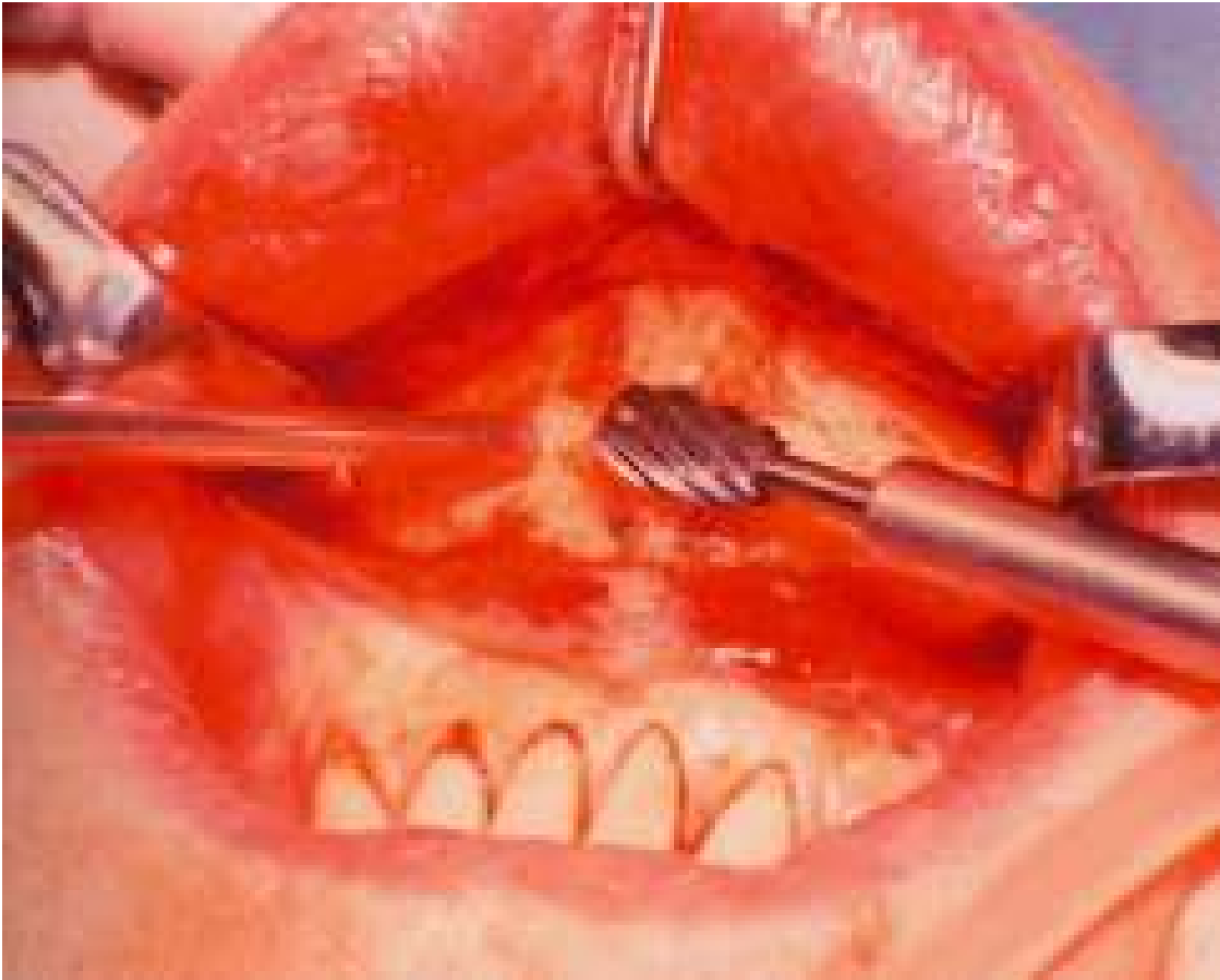LA MENTOPLASTICA

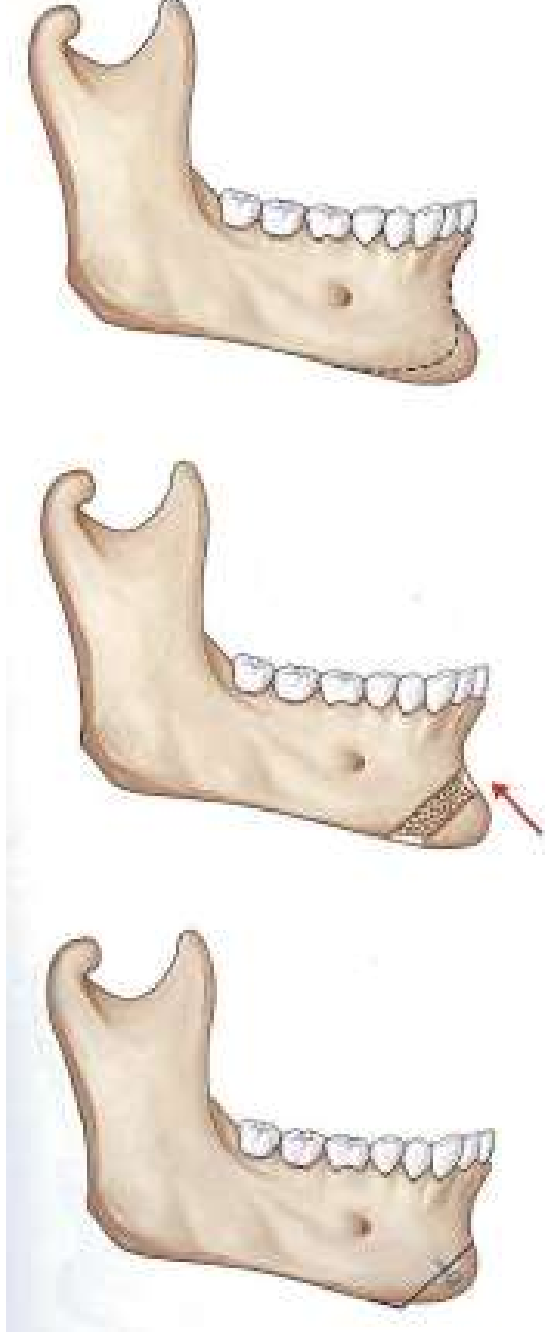
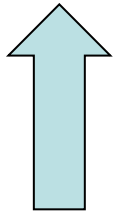
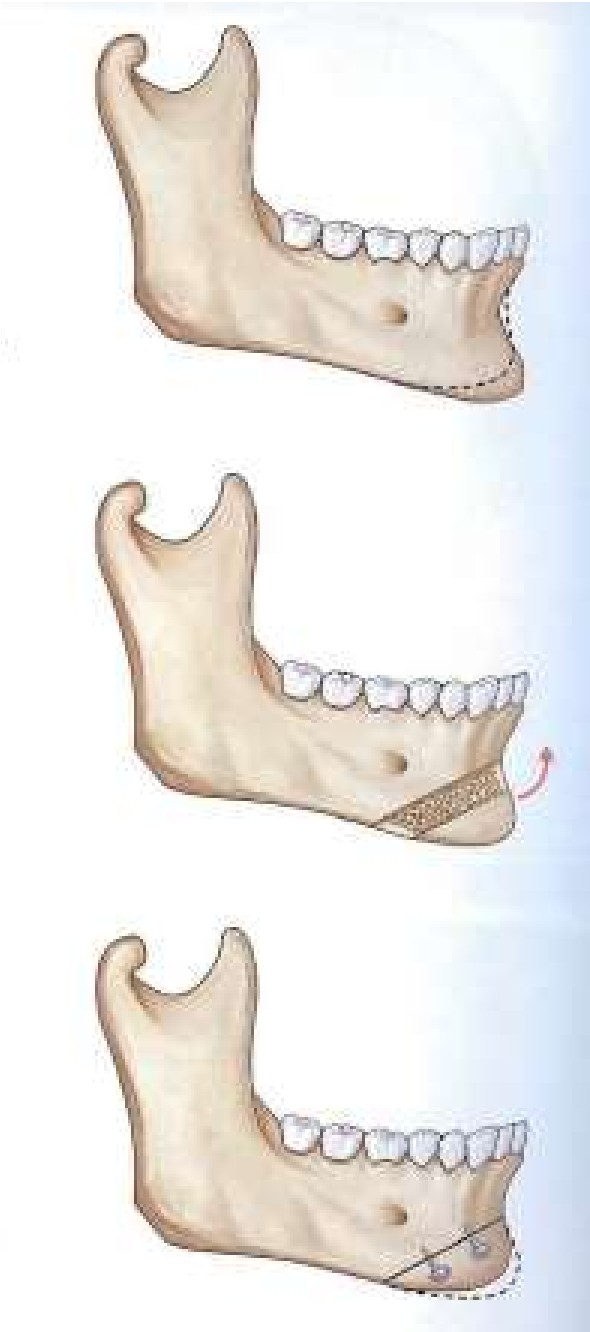


Regola!

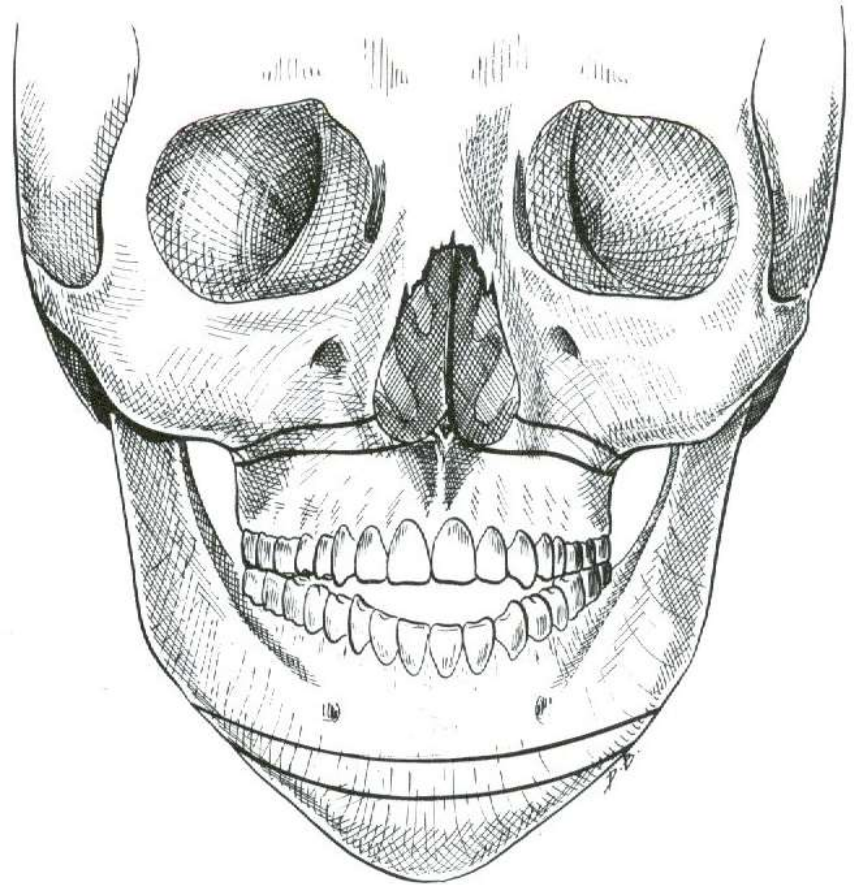
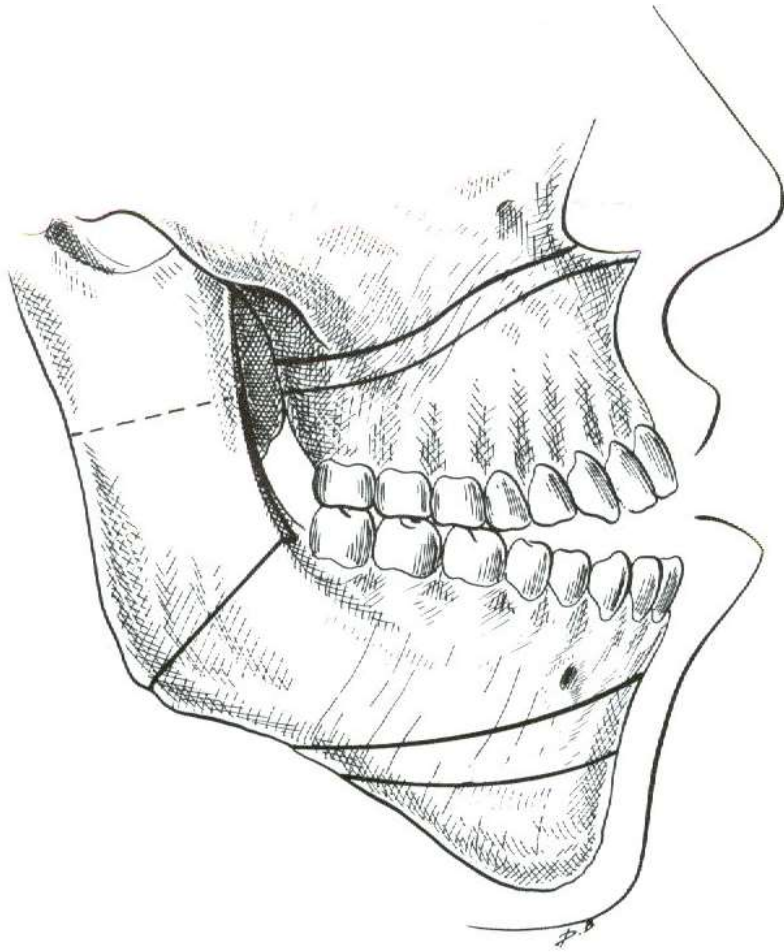
- ***Mai riduttiva con fresa!***

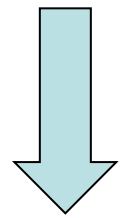
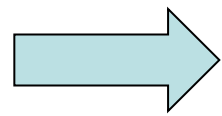
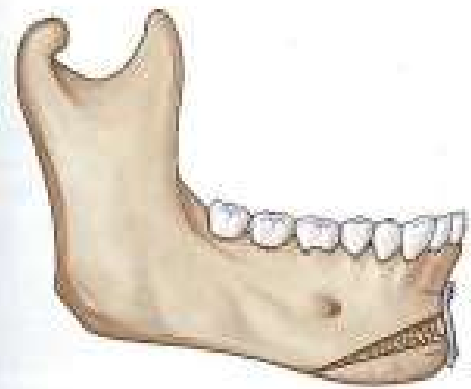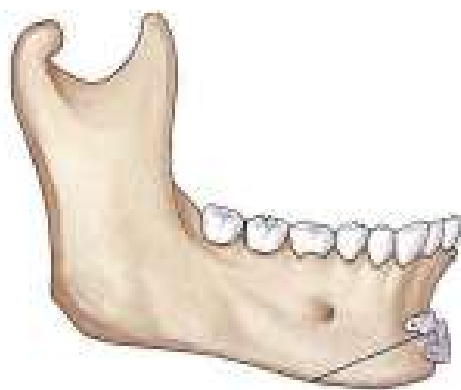

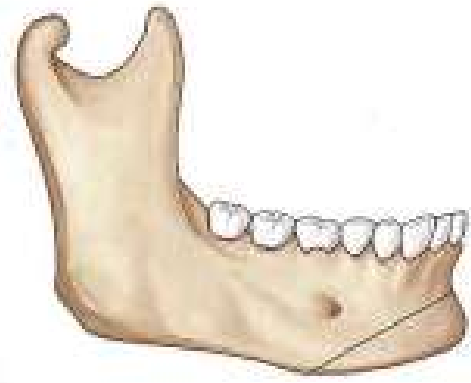
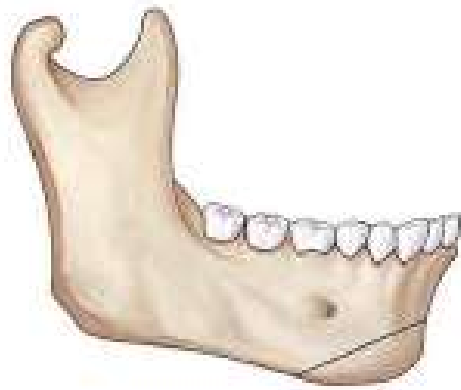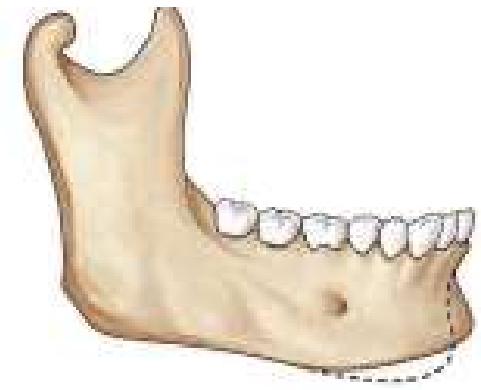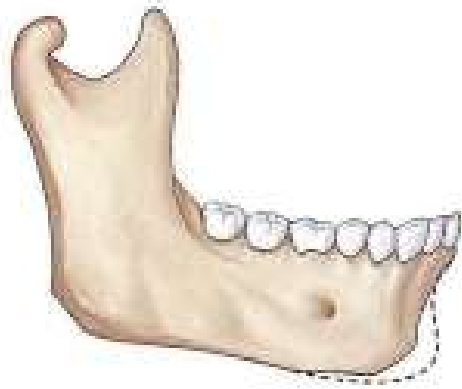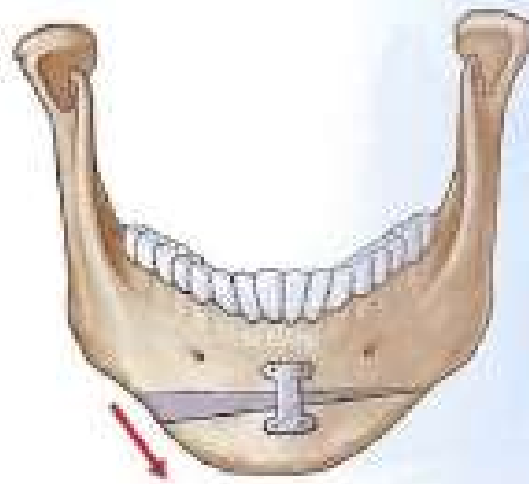
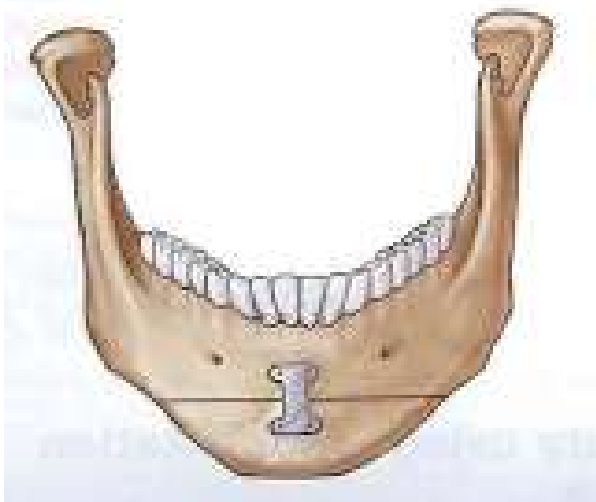
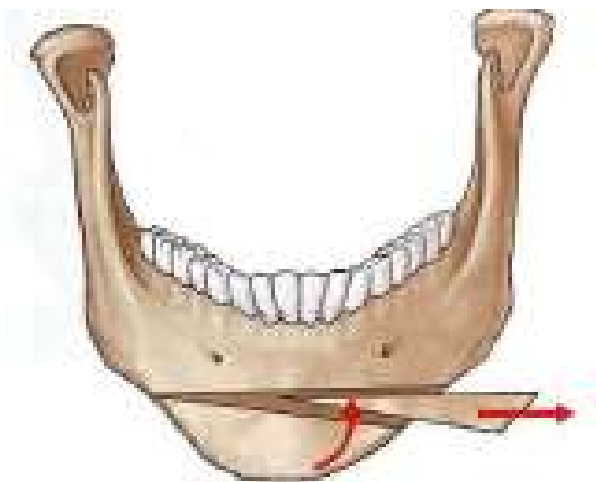


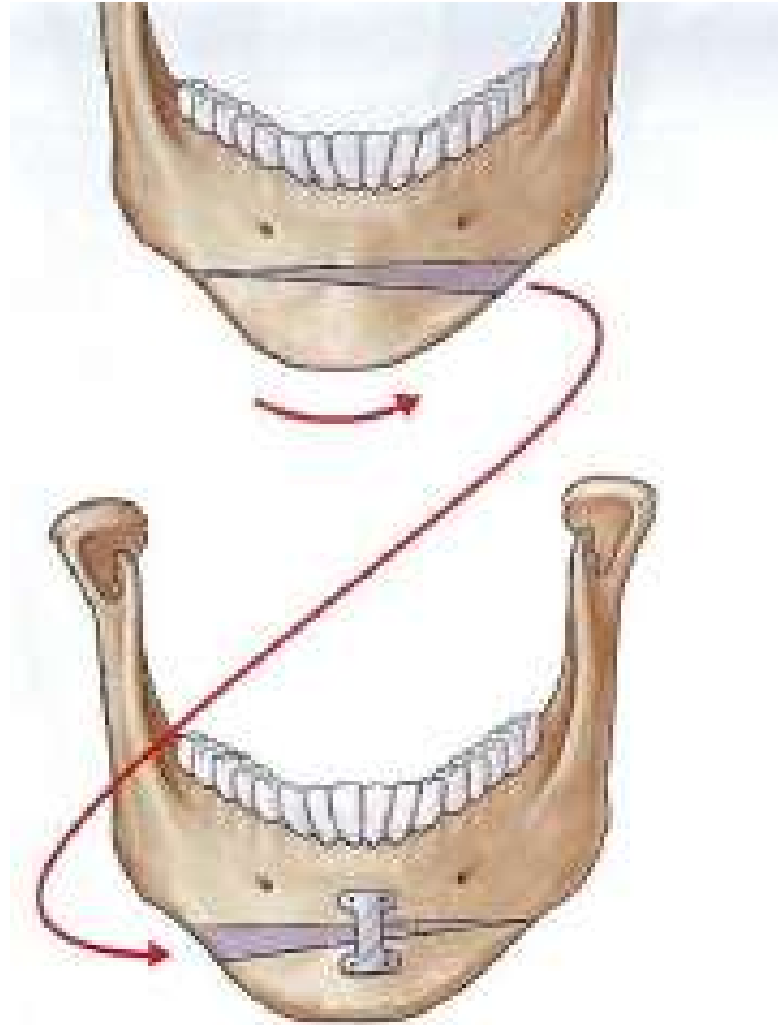


LA MENTOPLASTICA



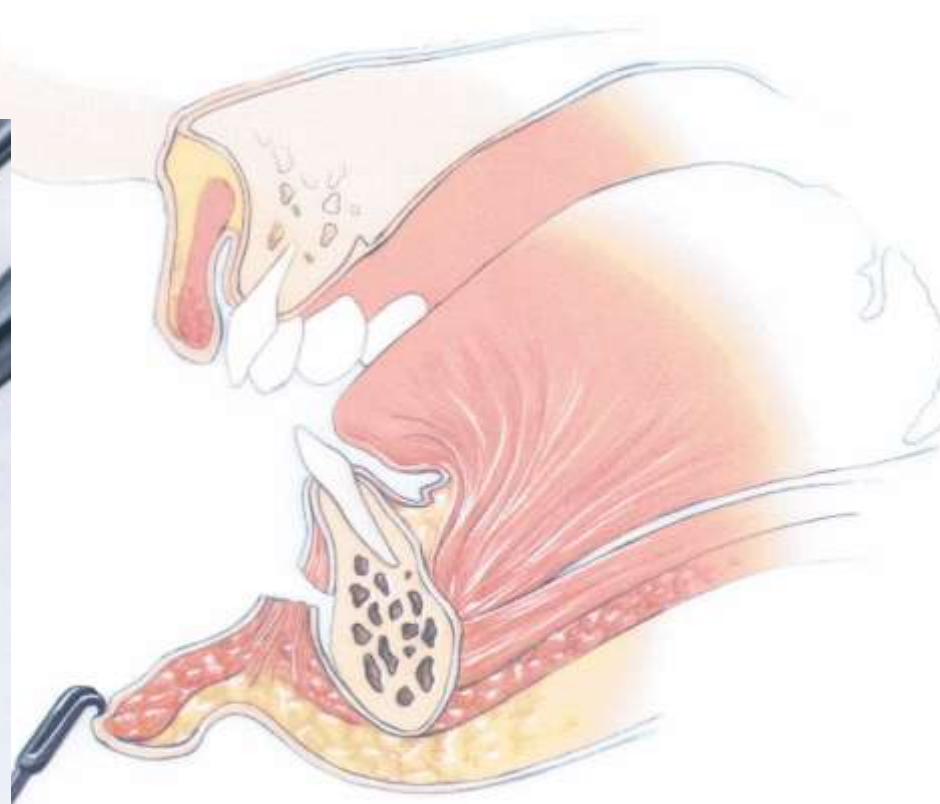
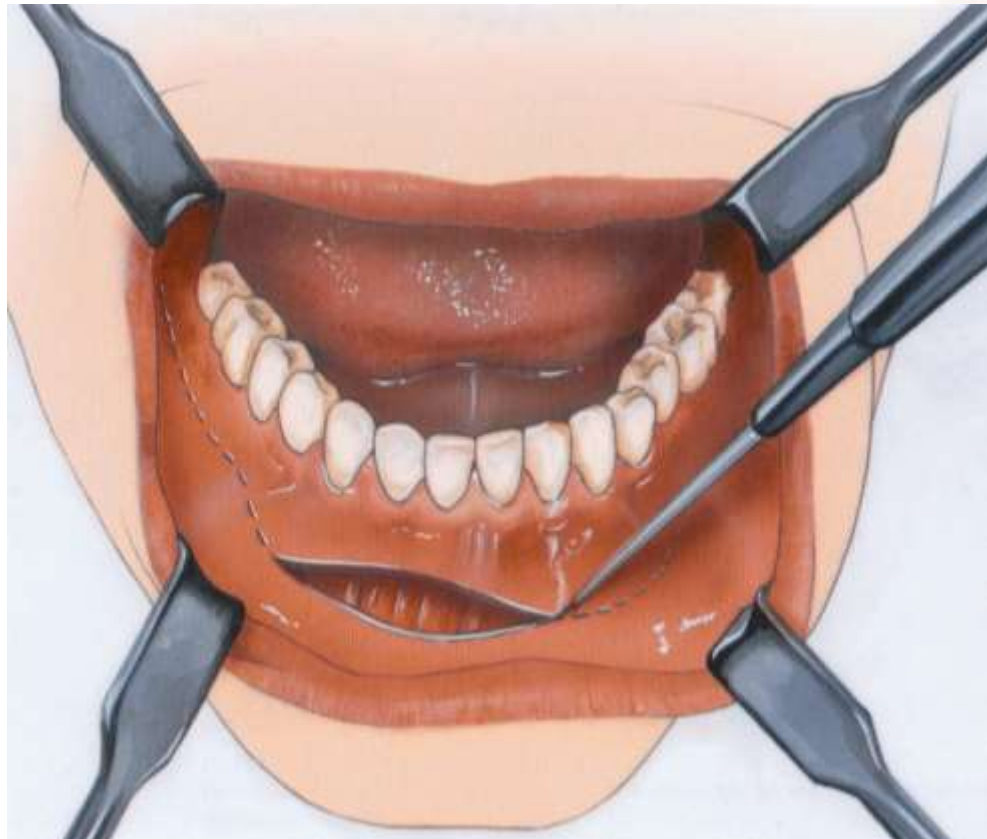




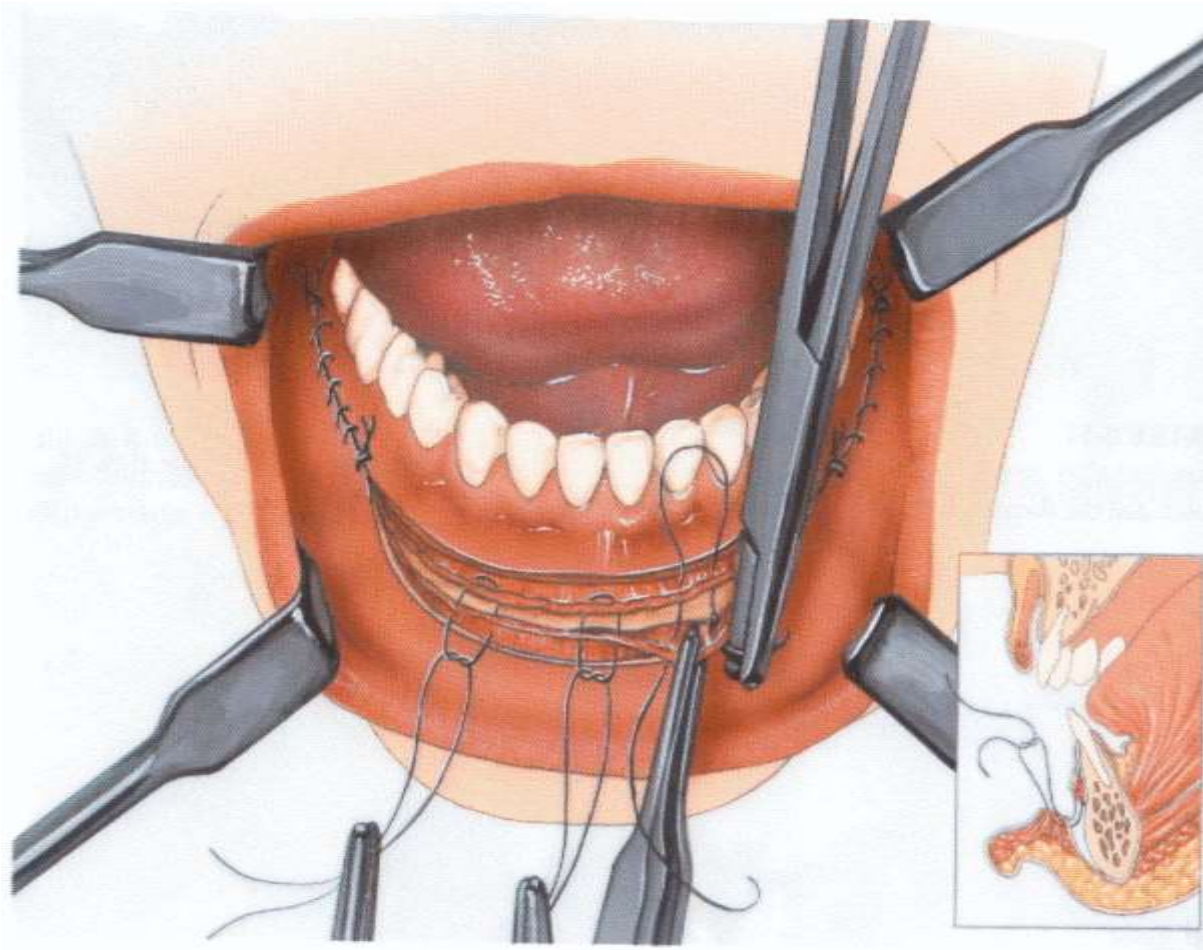


Regola!

- ***Incisione corretta...***

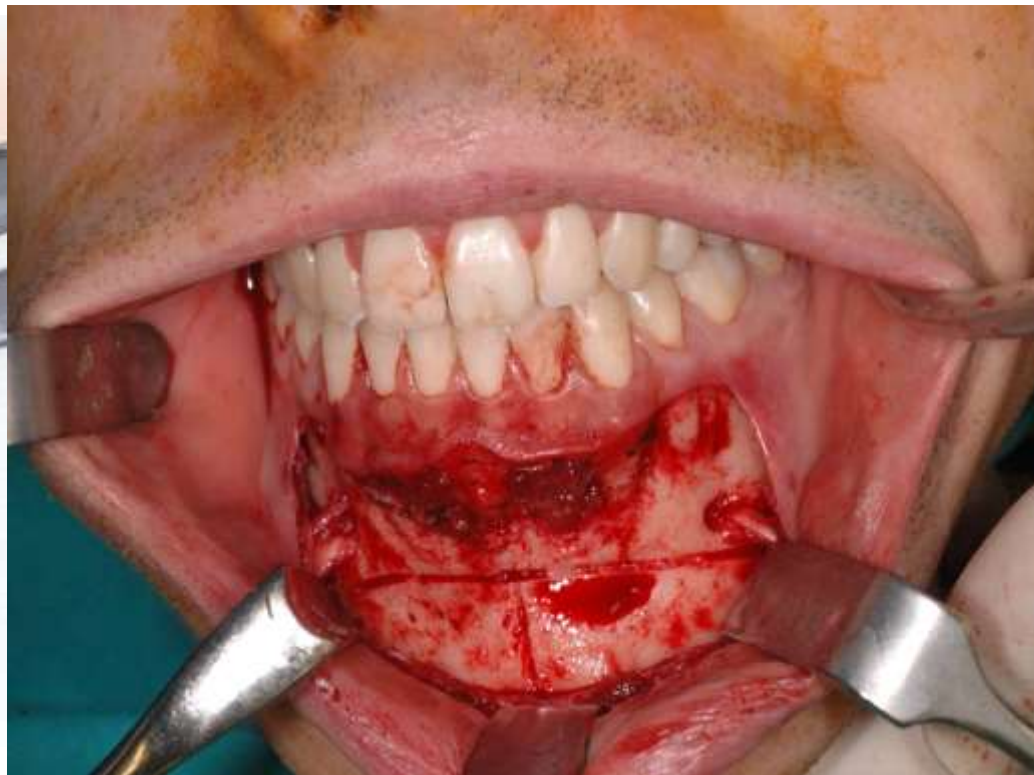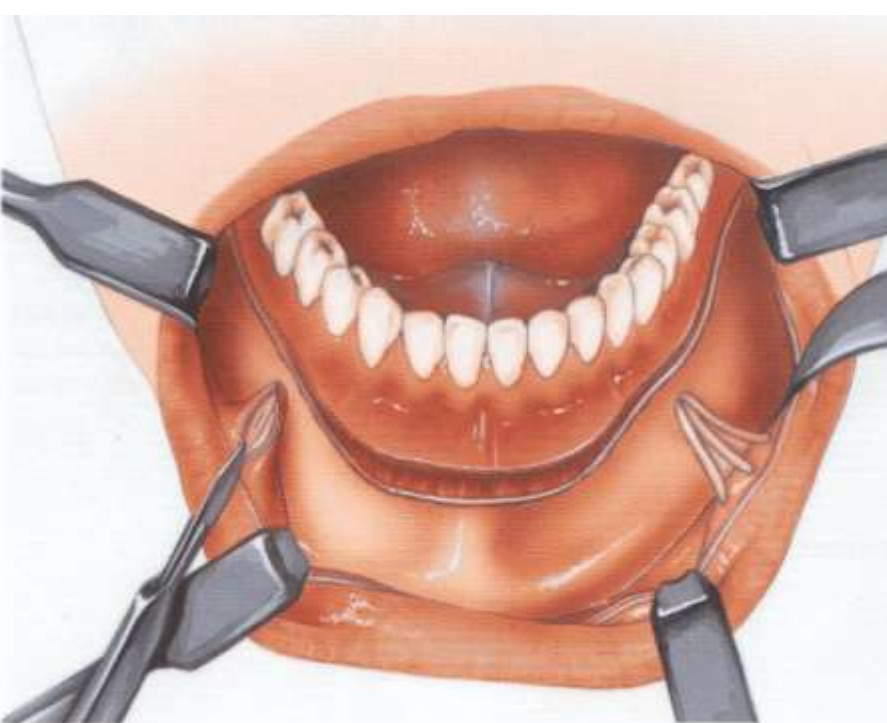


...per poter suturare correttamente

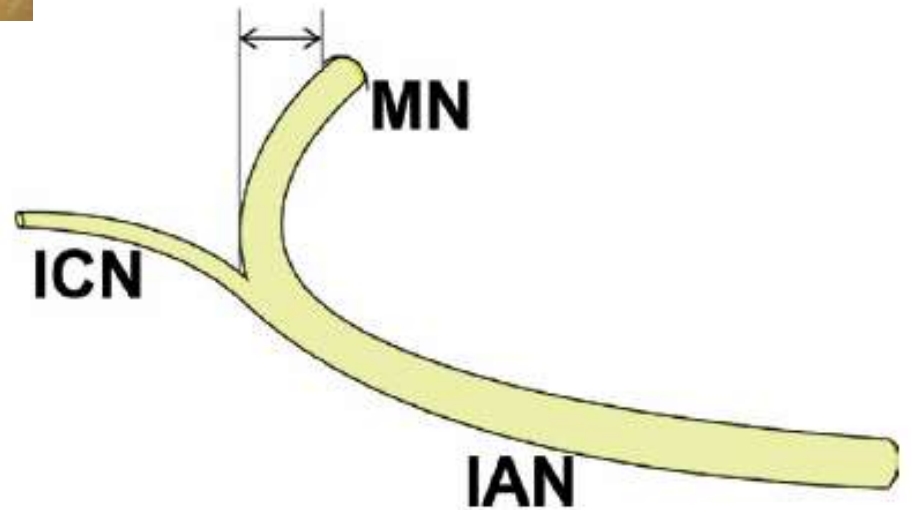
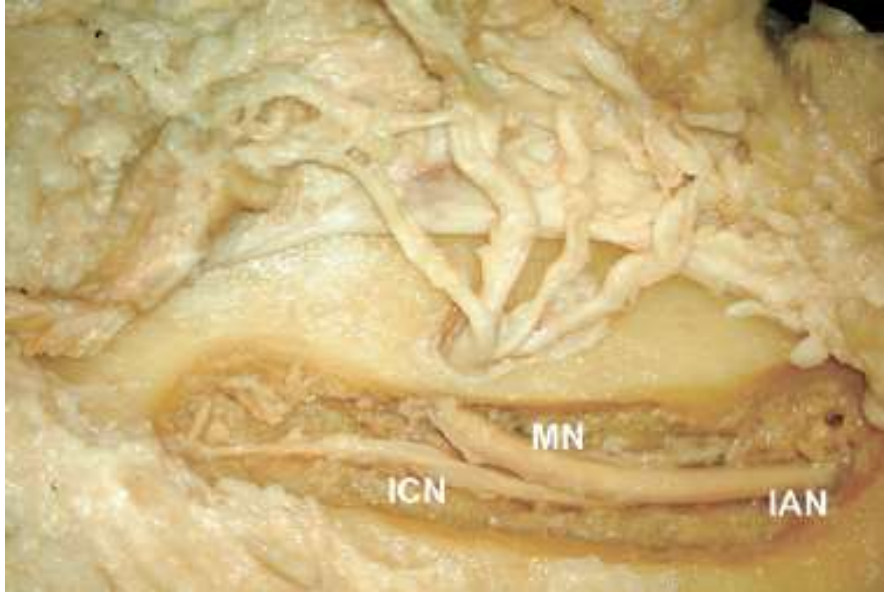


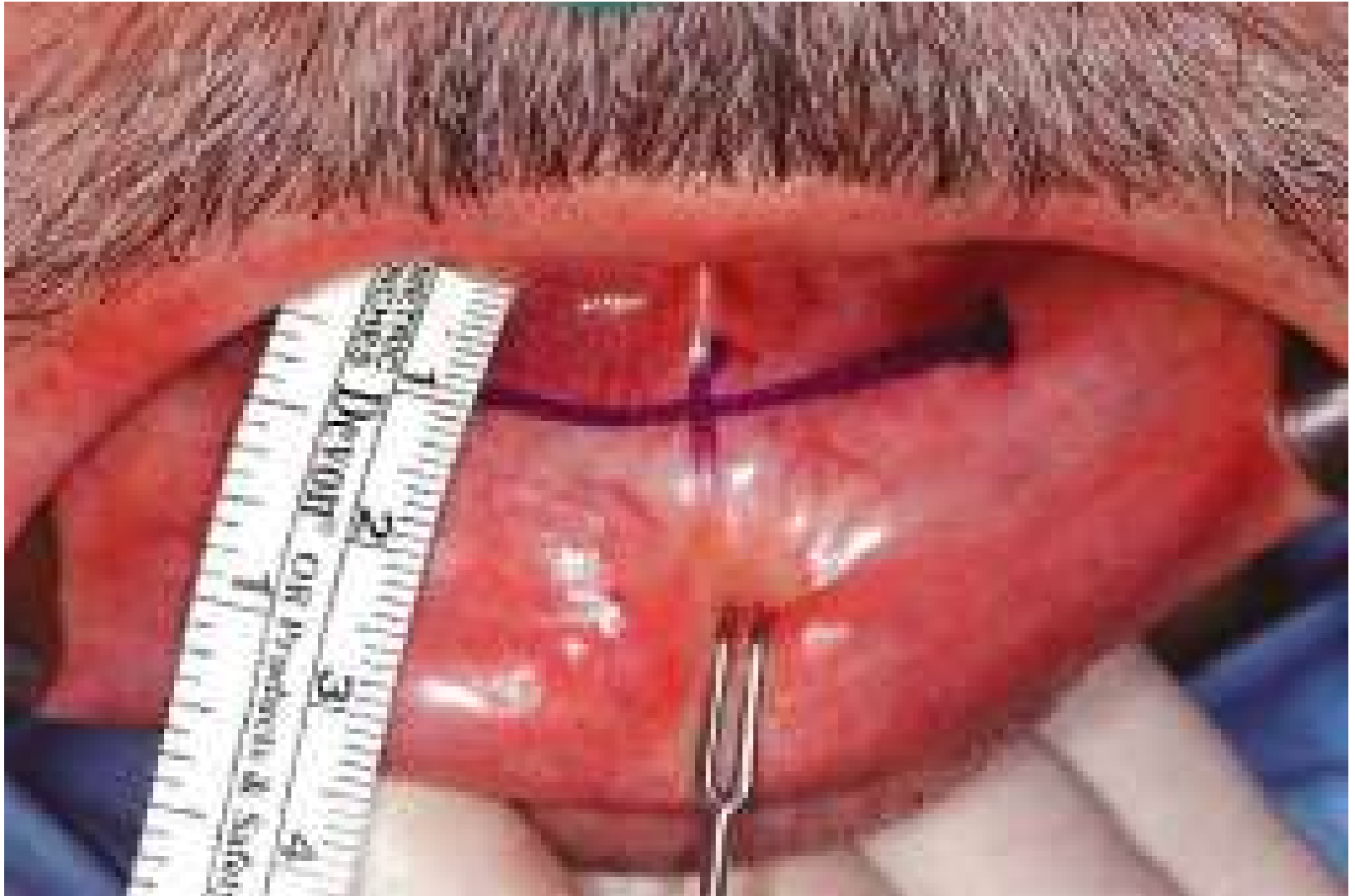Scheletrizzazione del mento

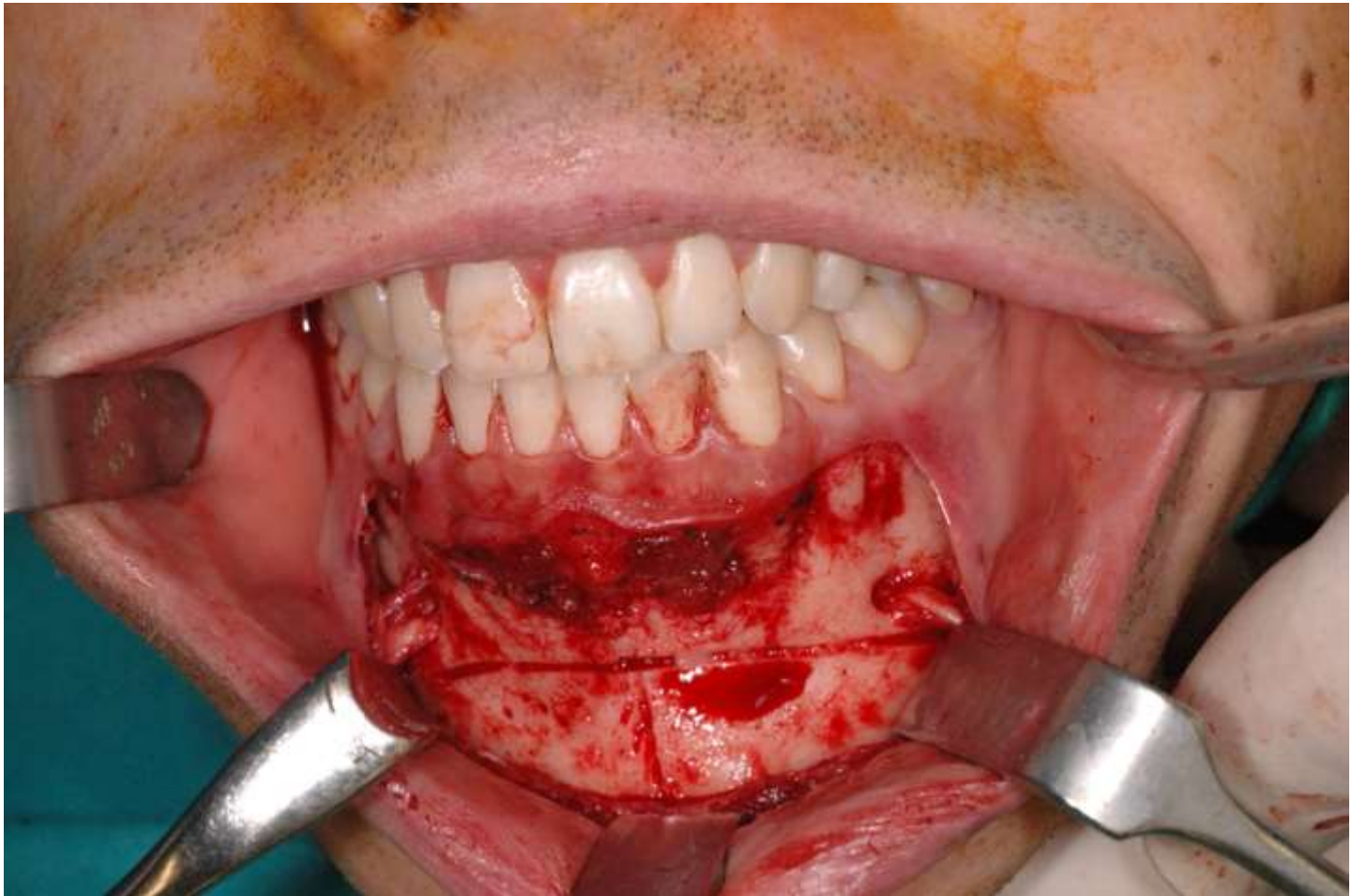
Attenzione al nervo mentoniero!

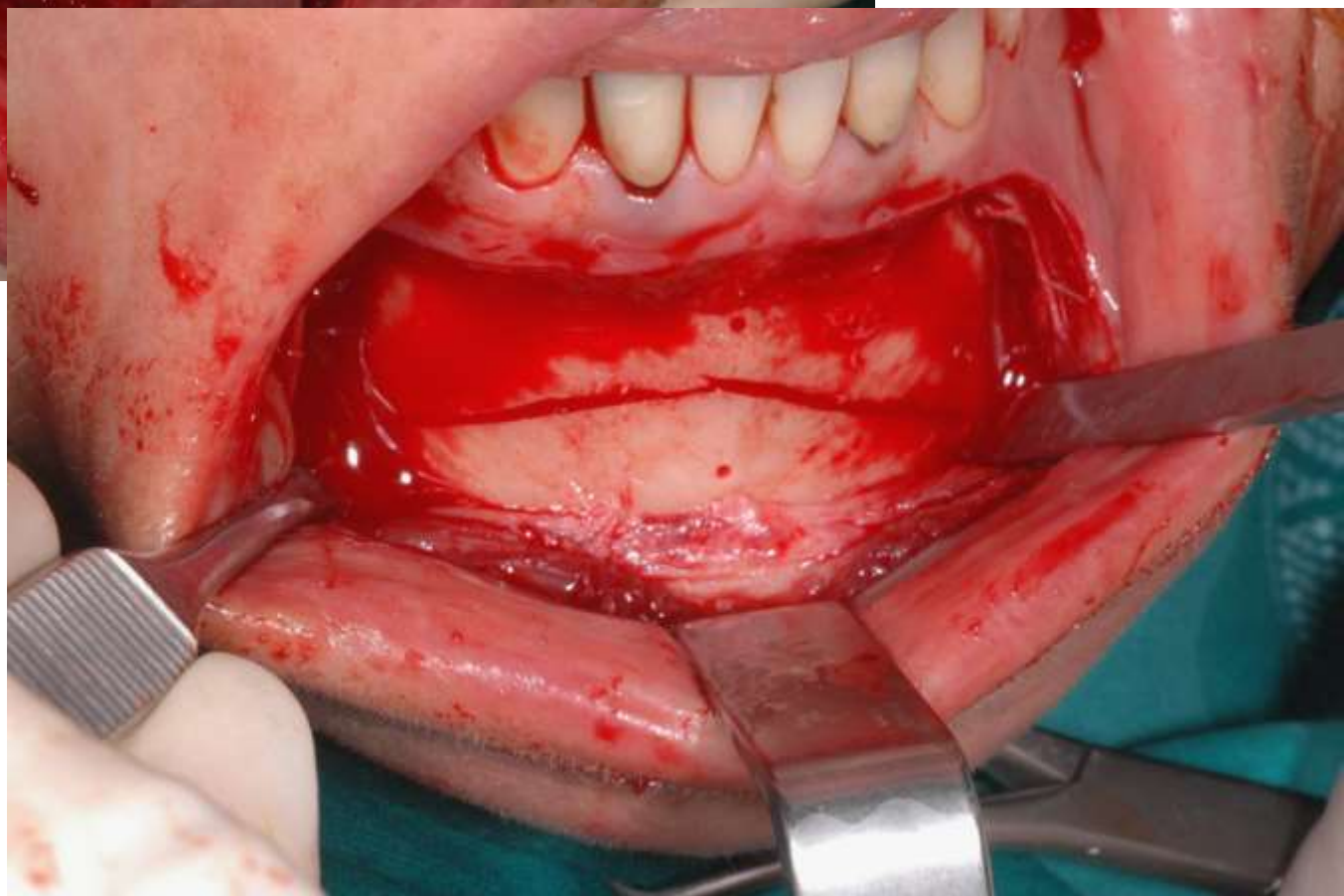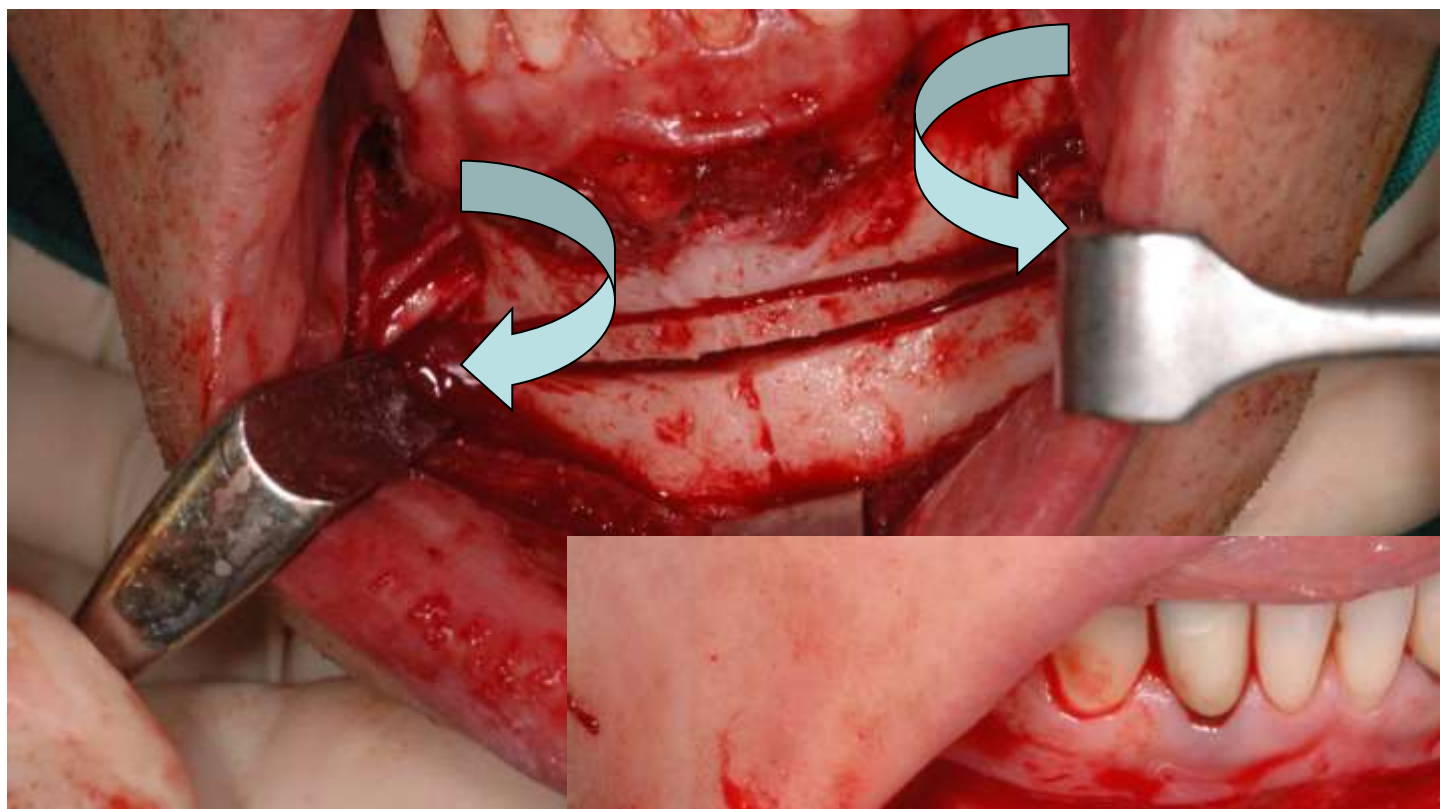


LA MENTOPLASTICA

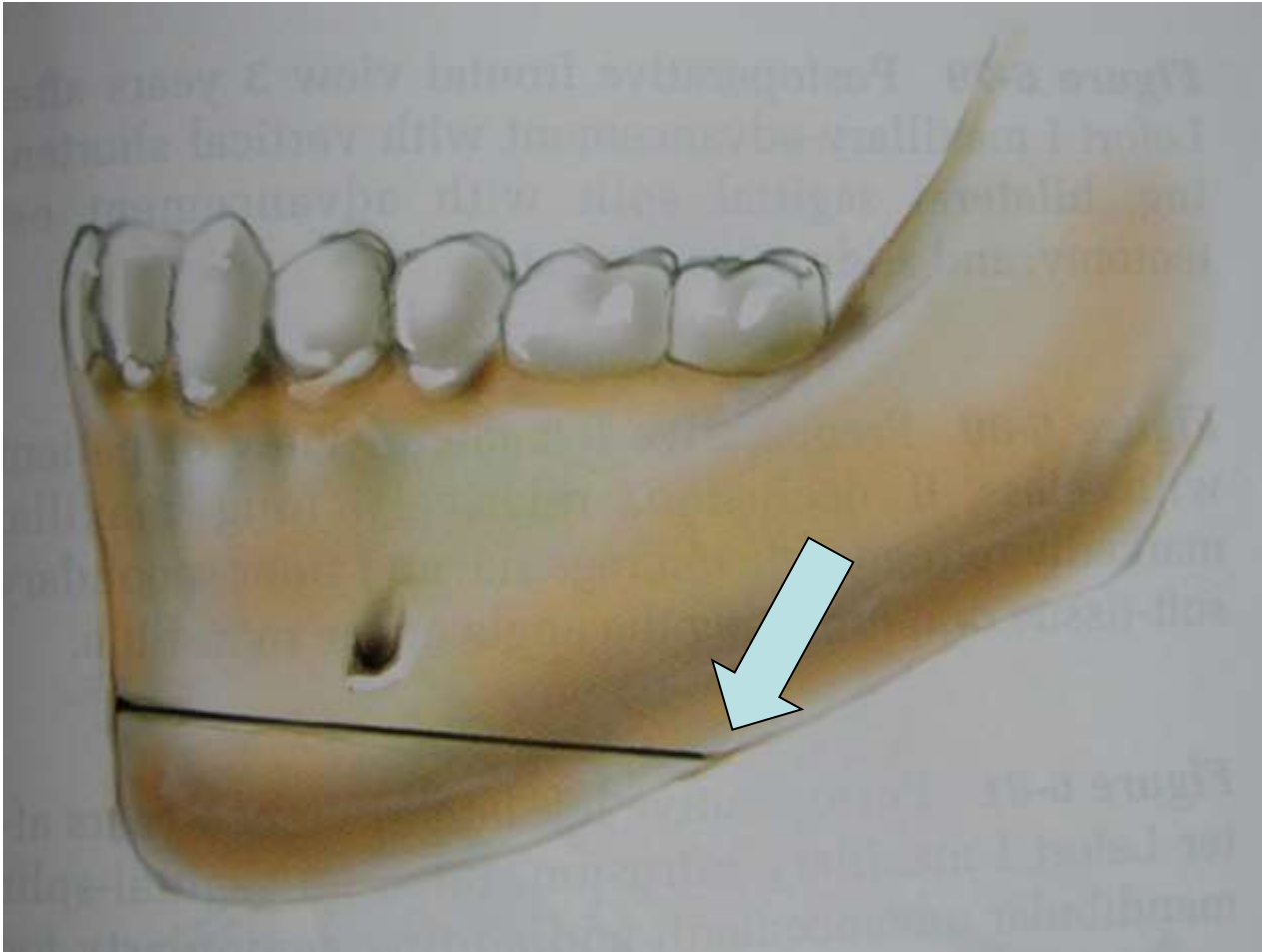




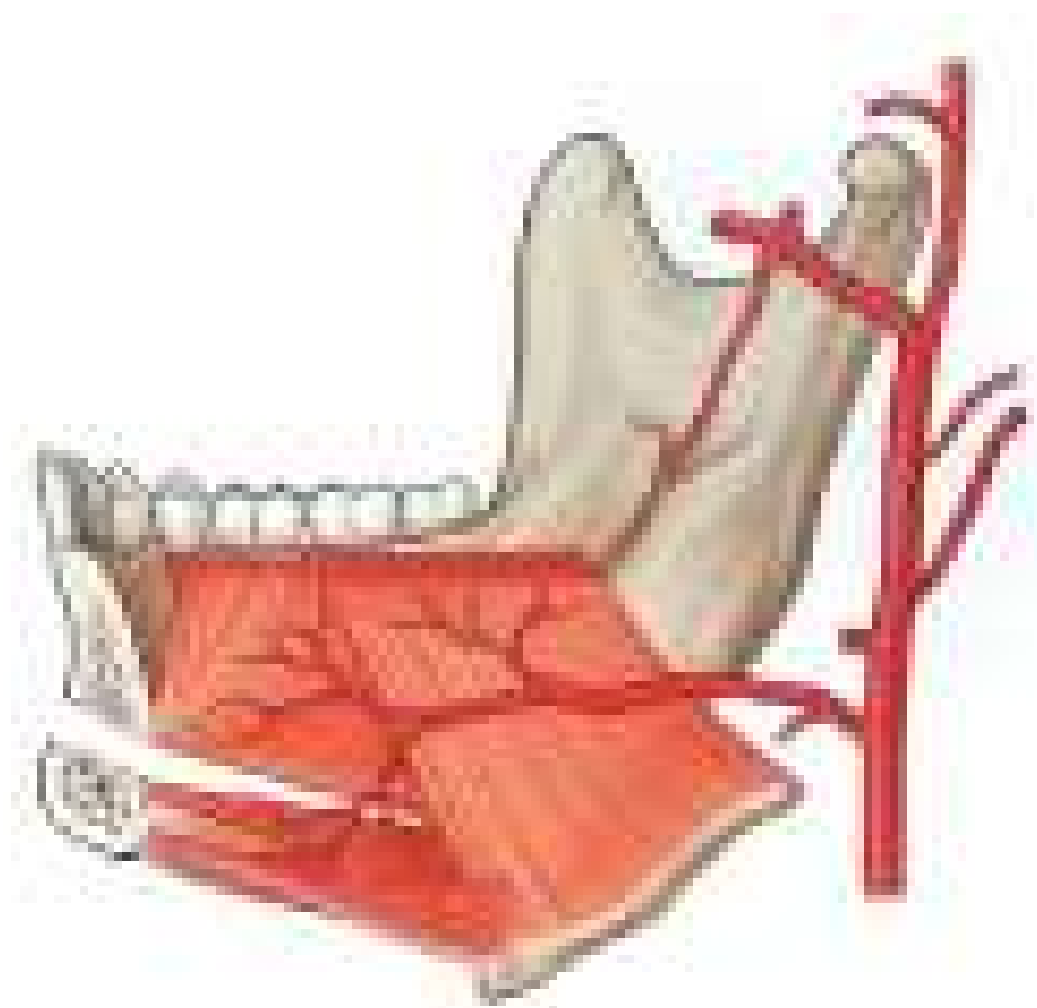



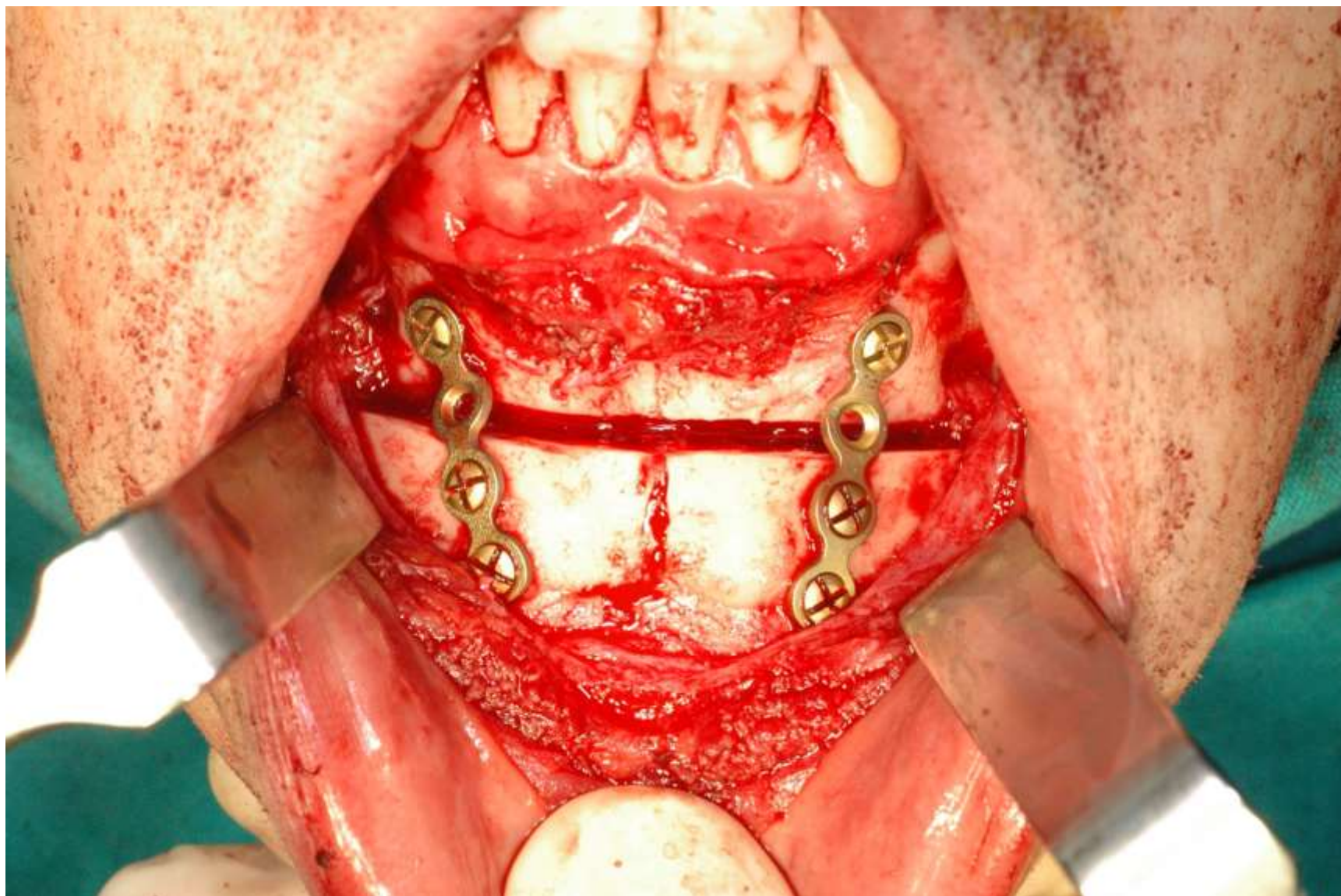
Regola!

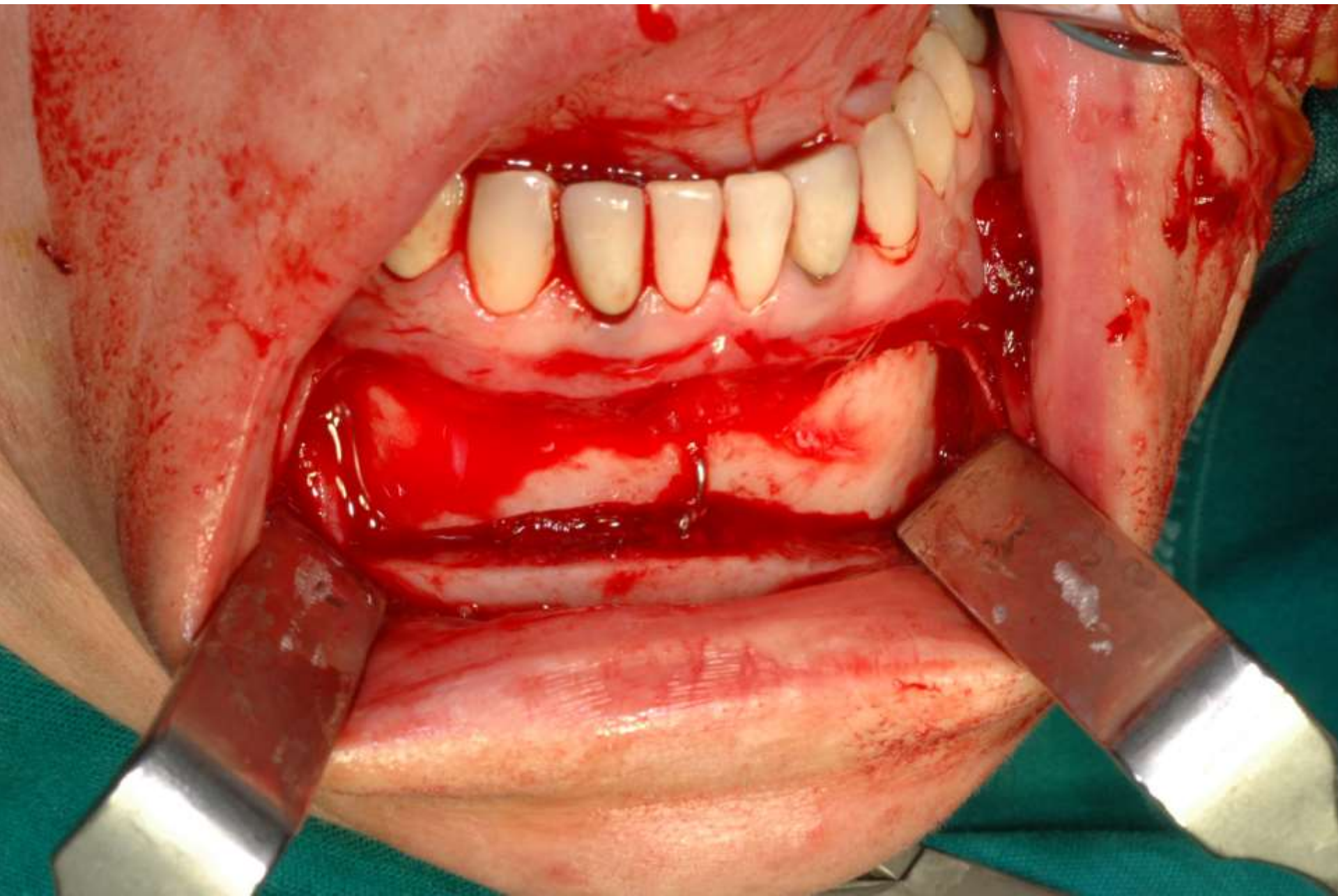


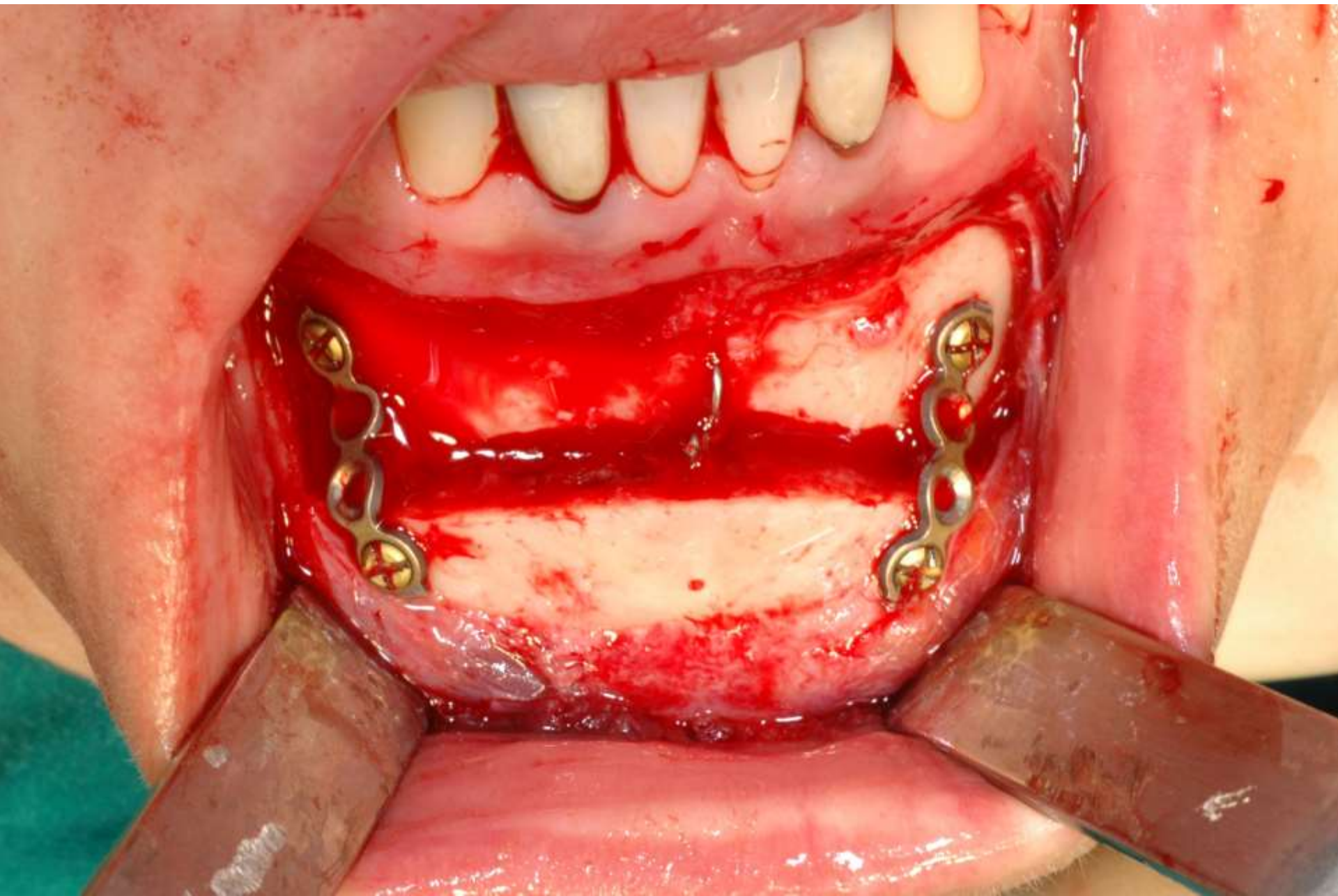
Interrompere accuratamente il bordo posteriore

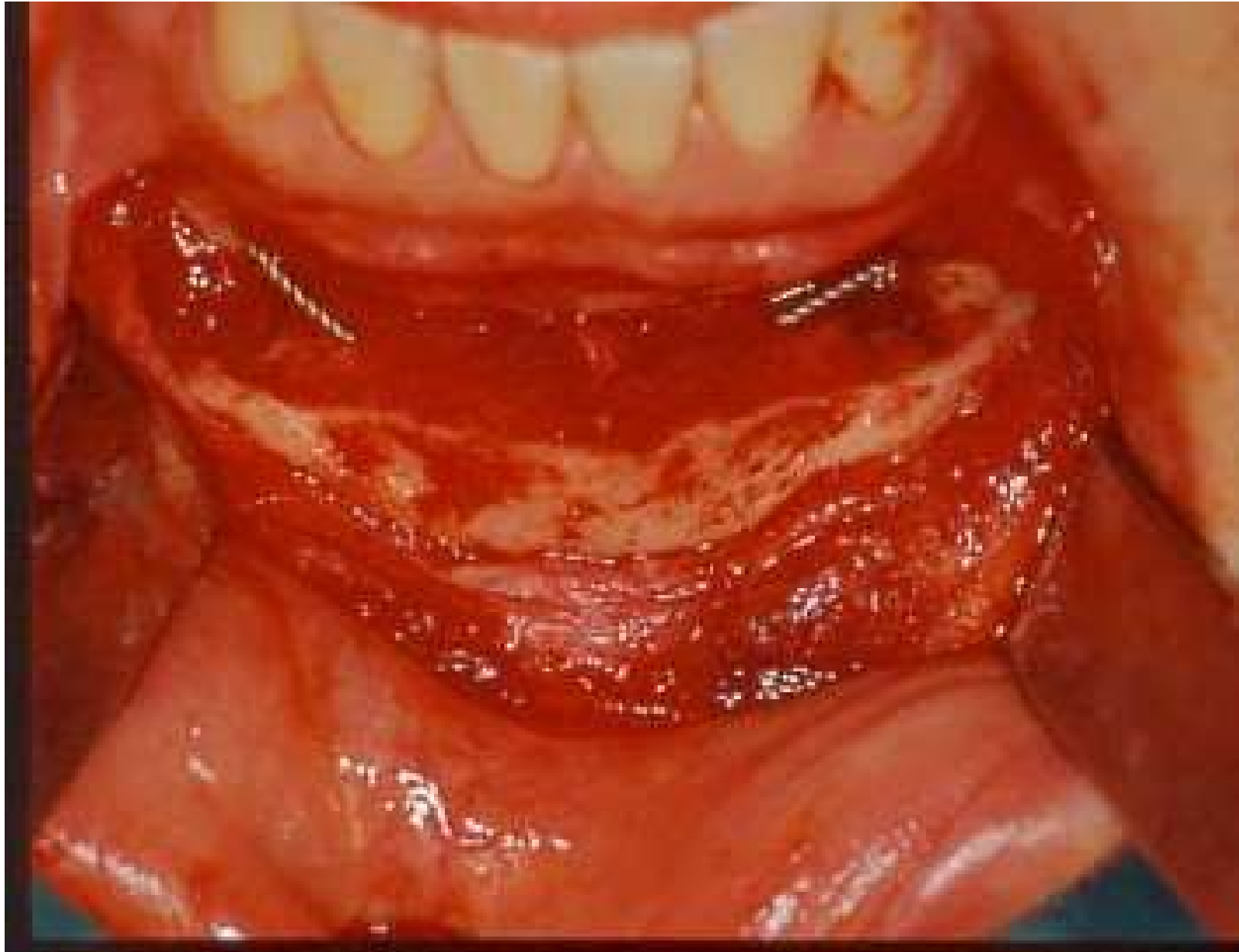

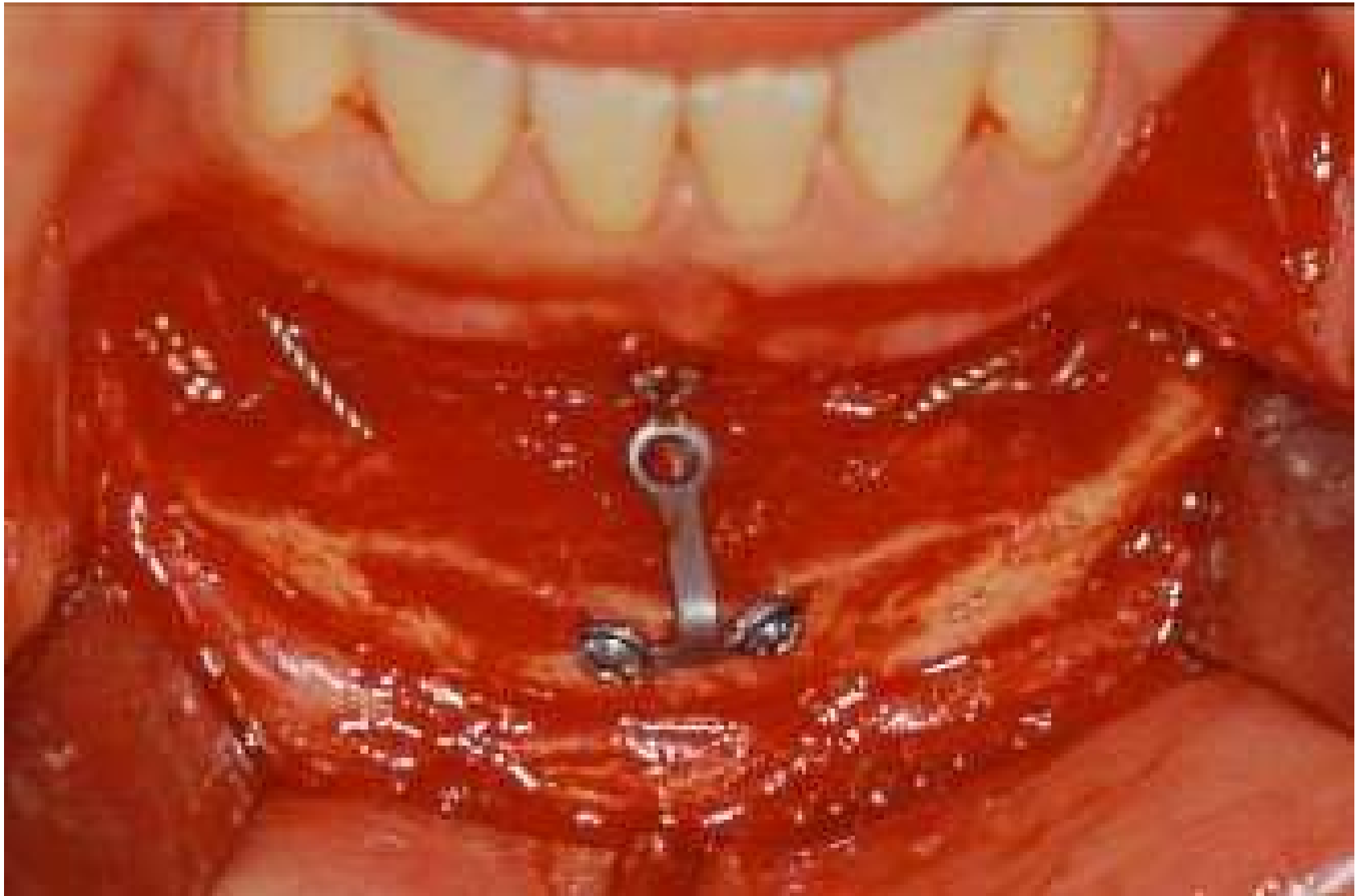fissazione



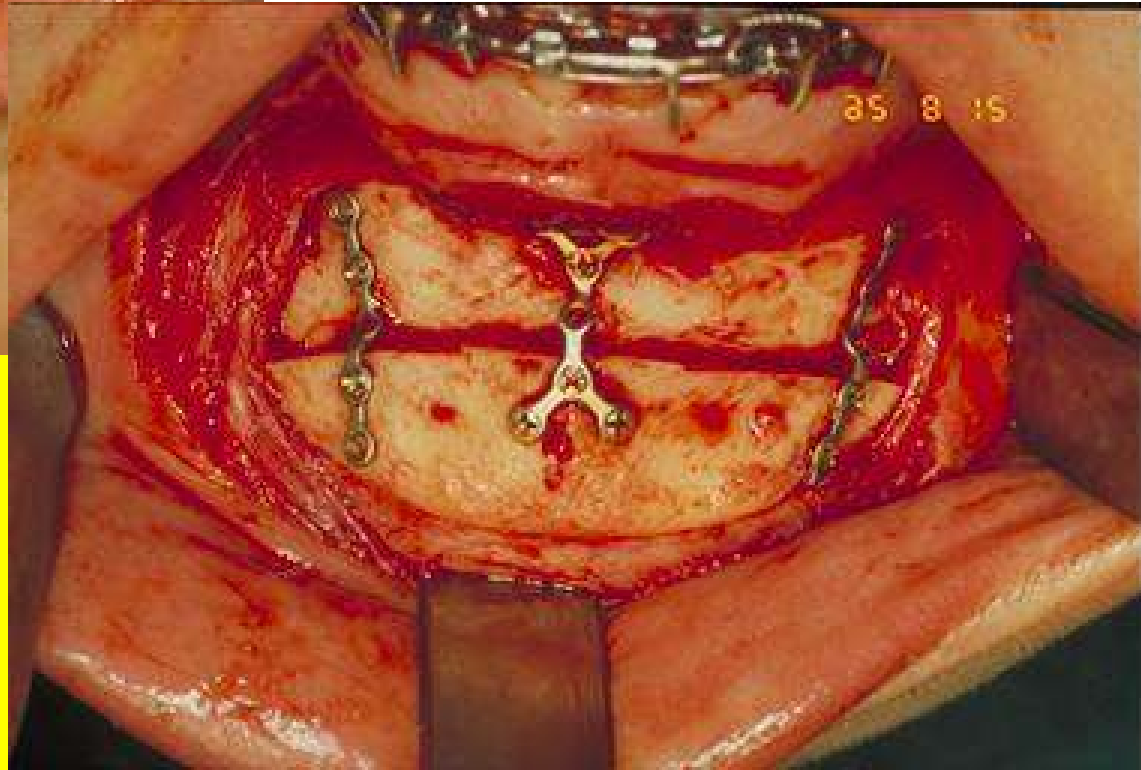
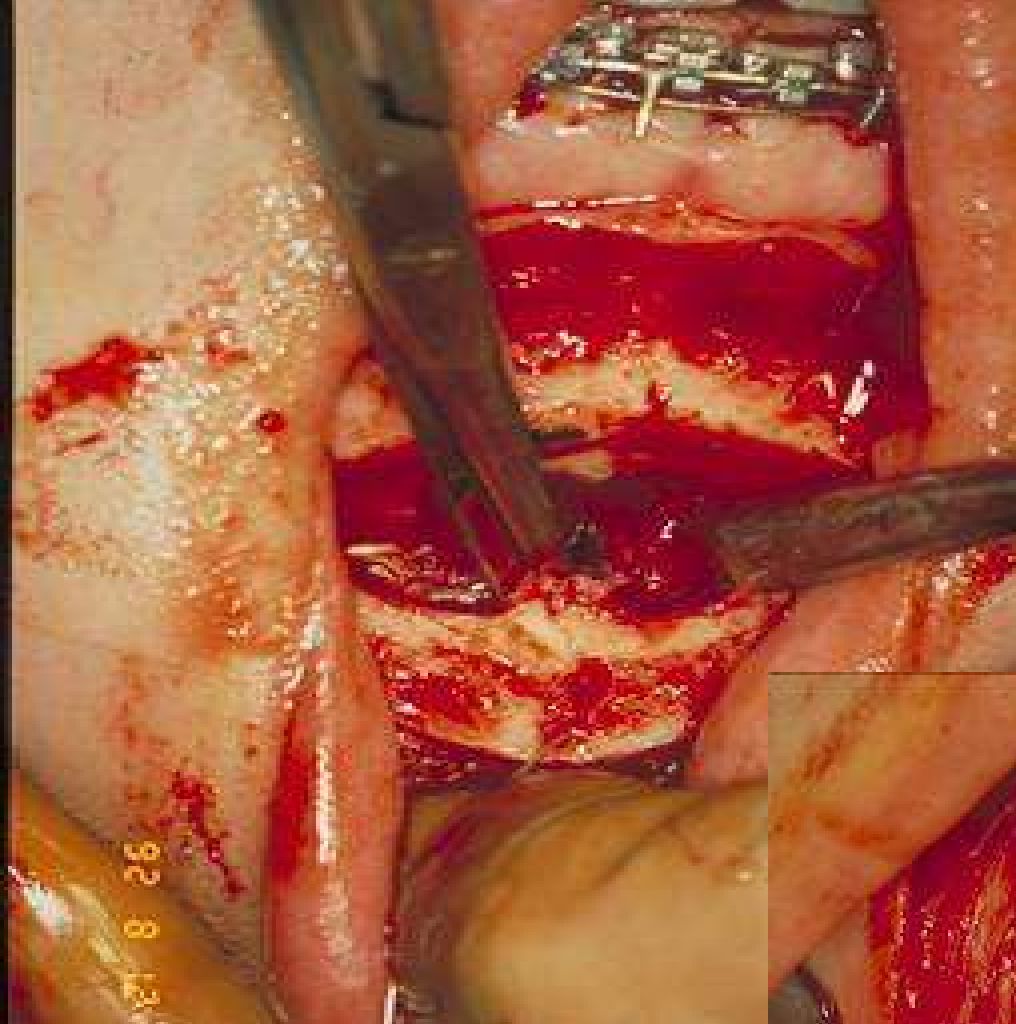




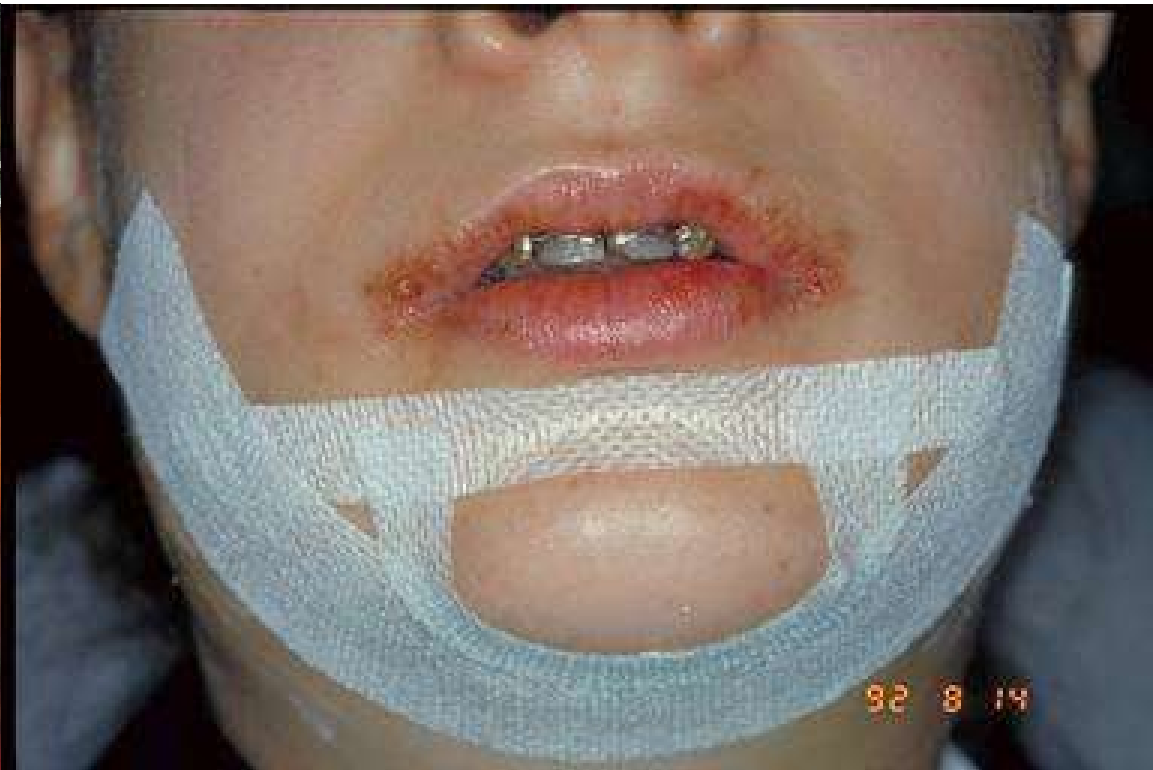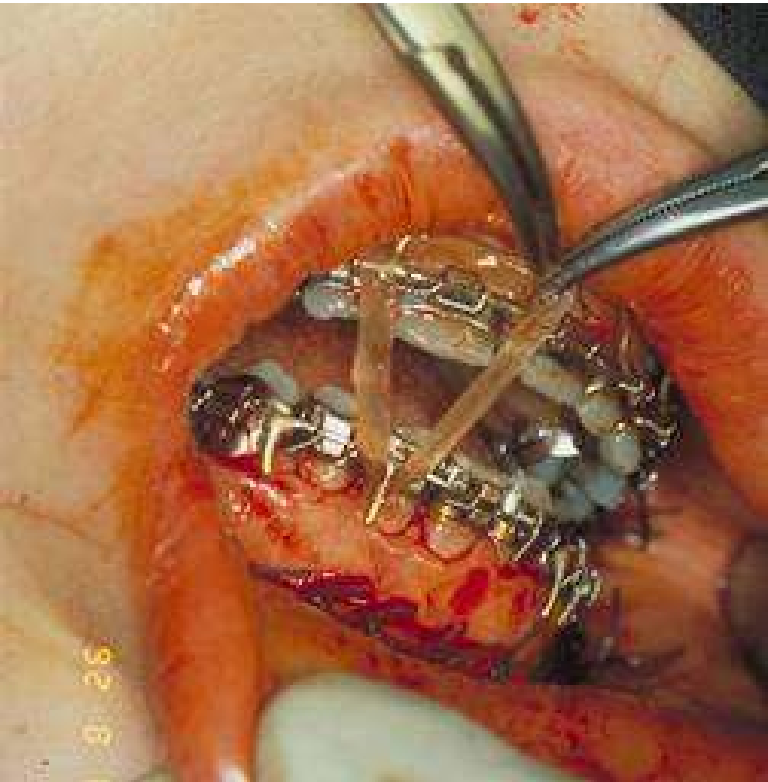




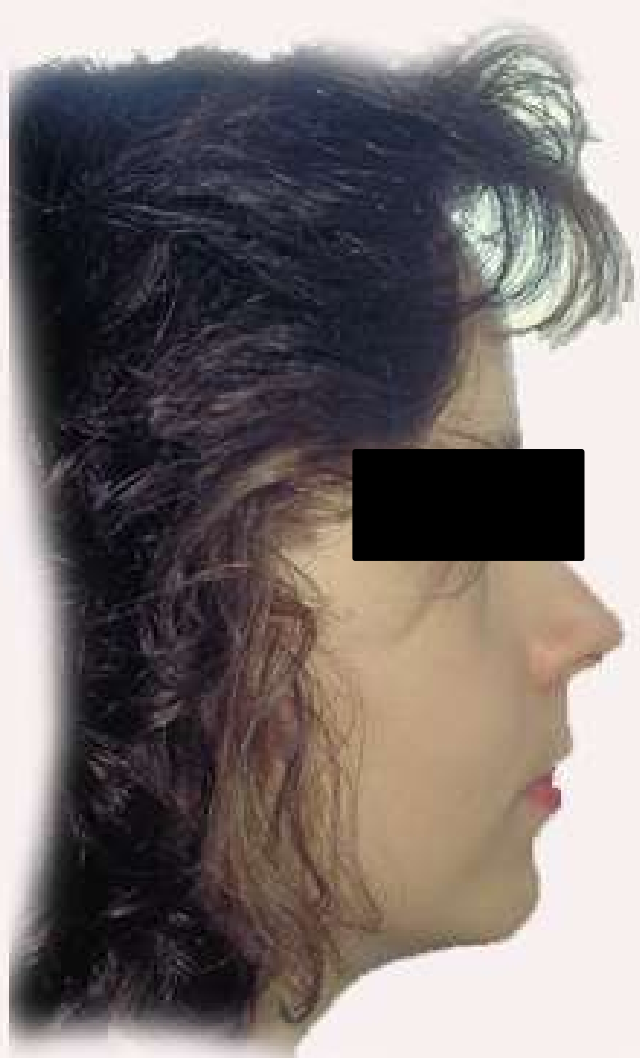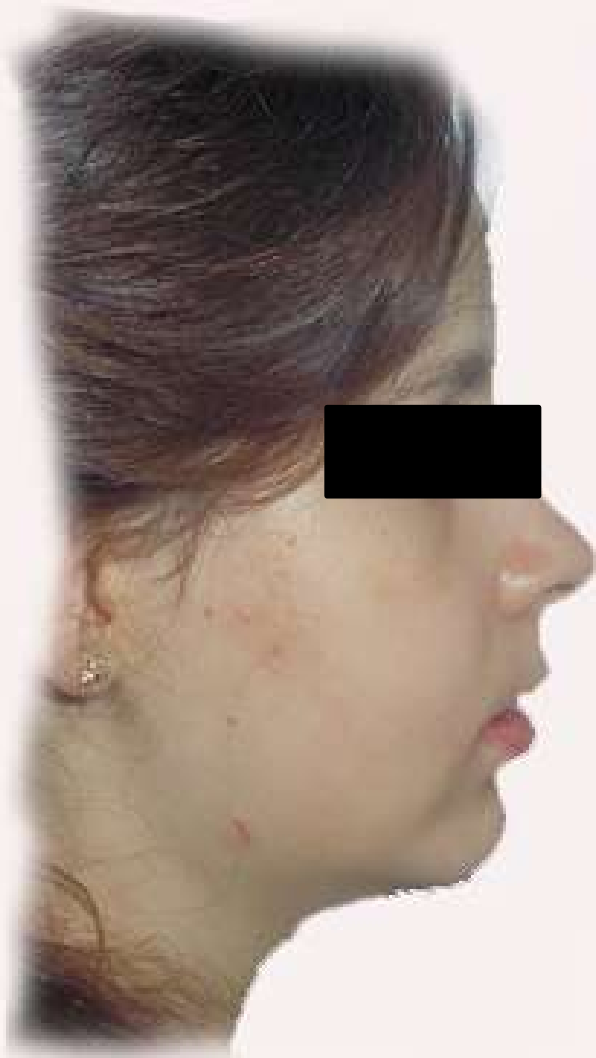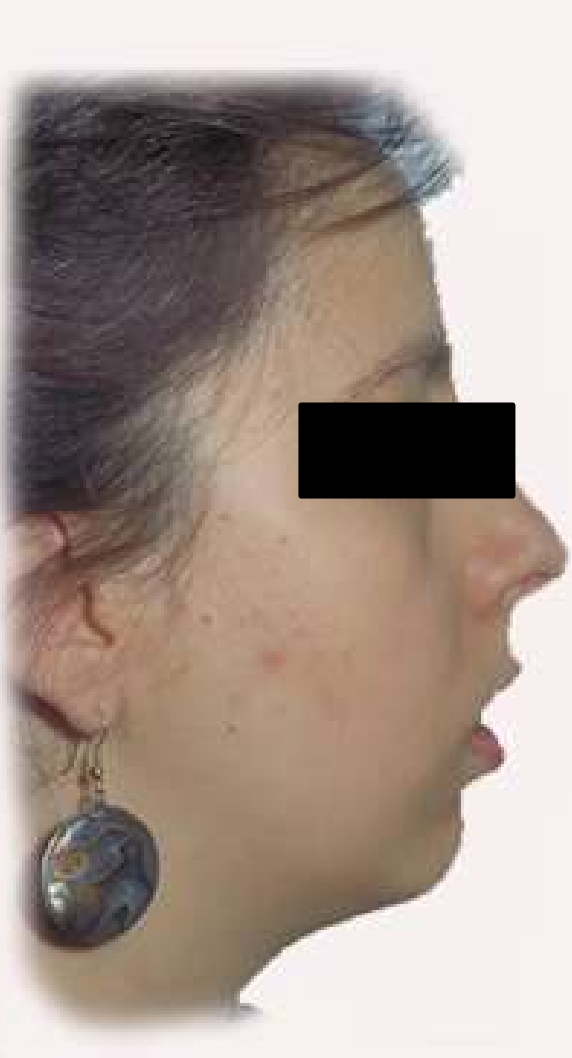Miotomia?

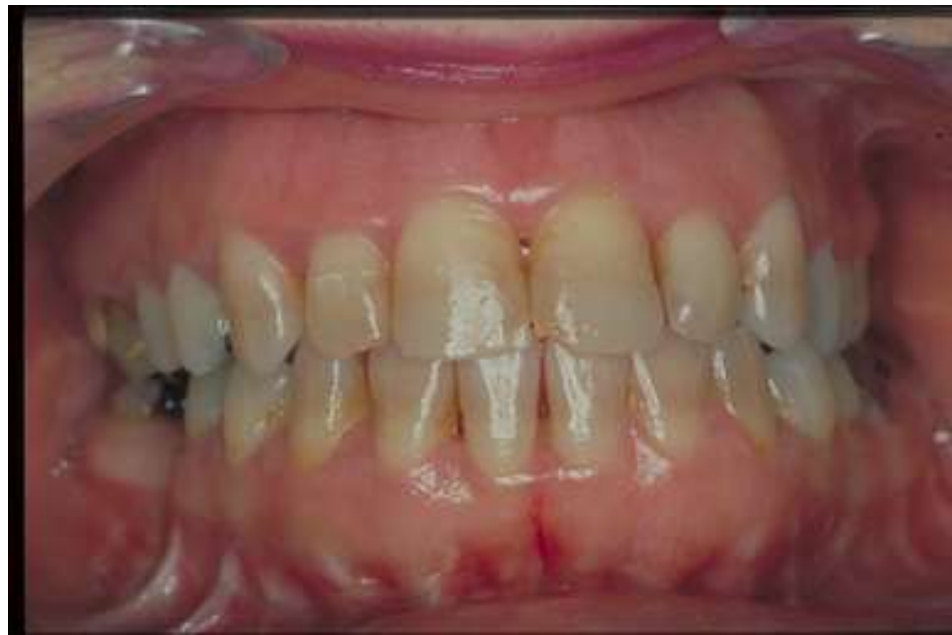
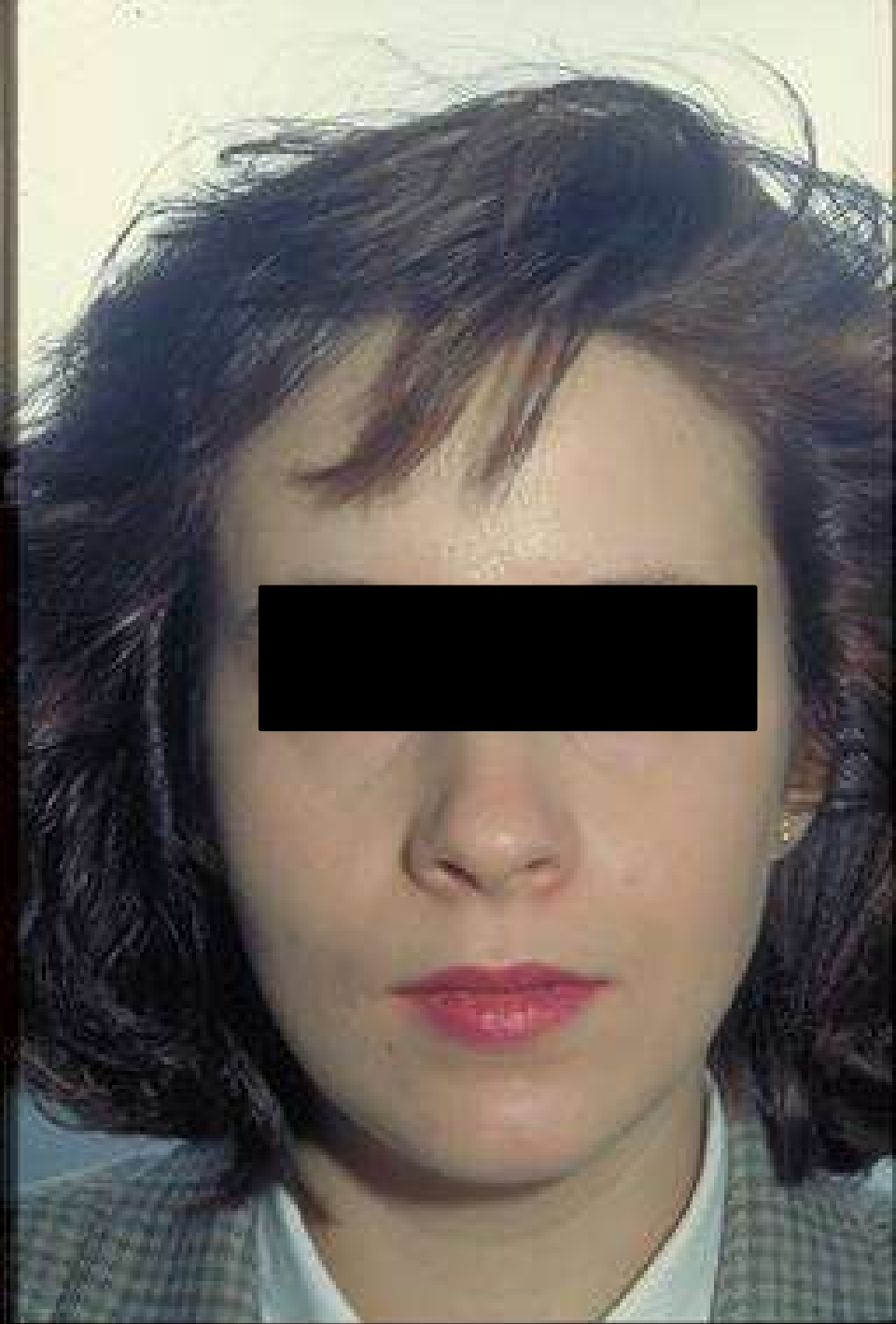
Regola!



contenzione cutanea

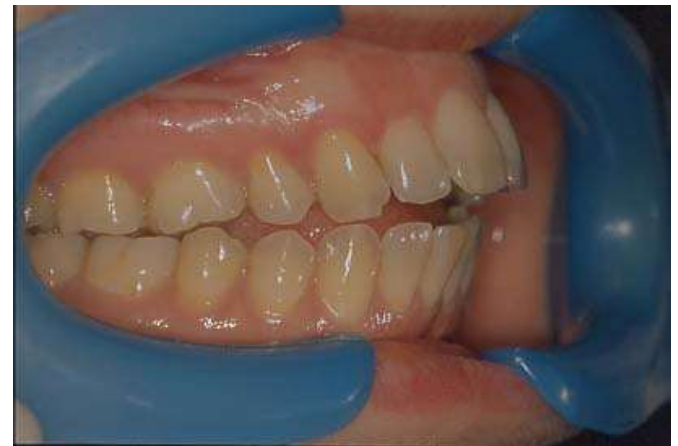
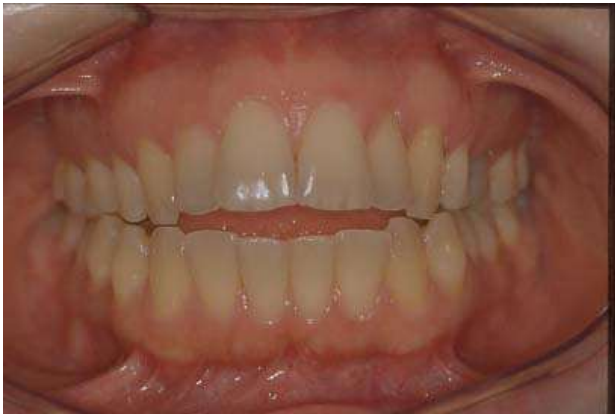
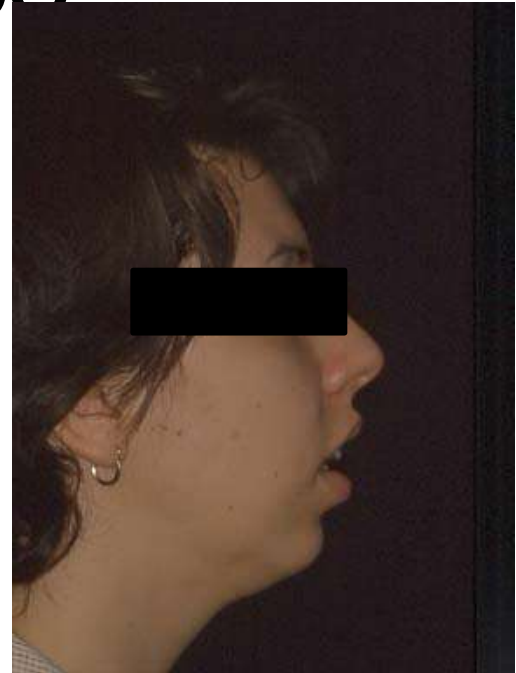
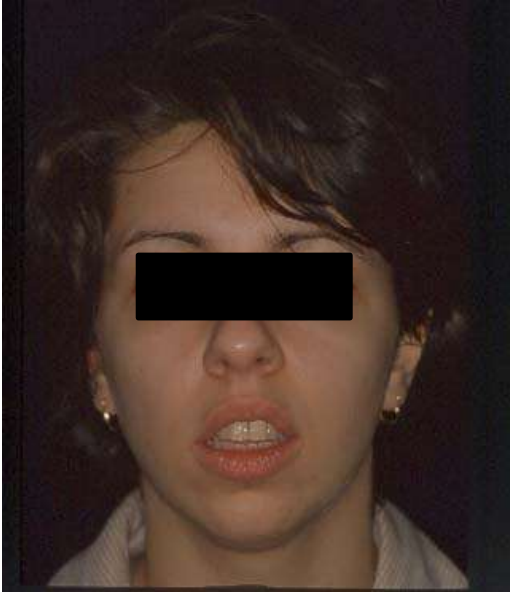
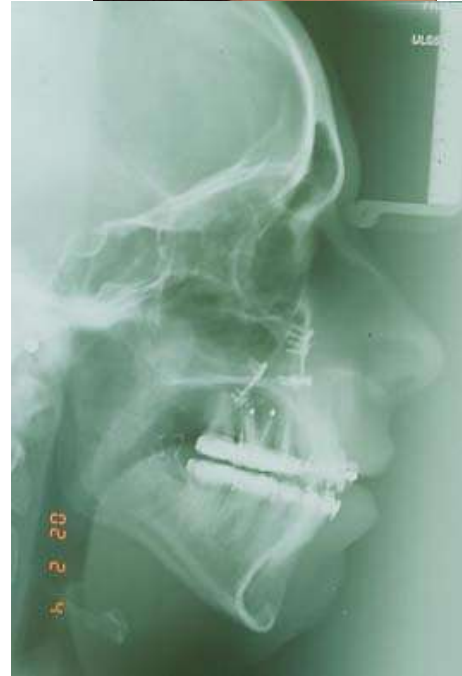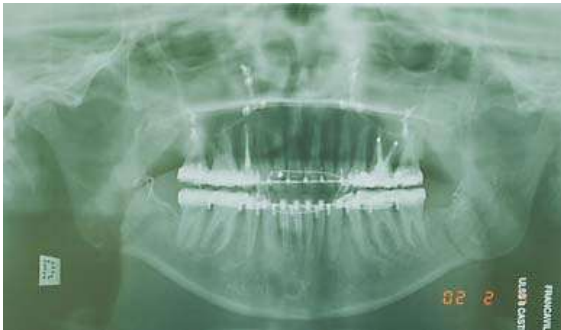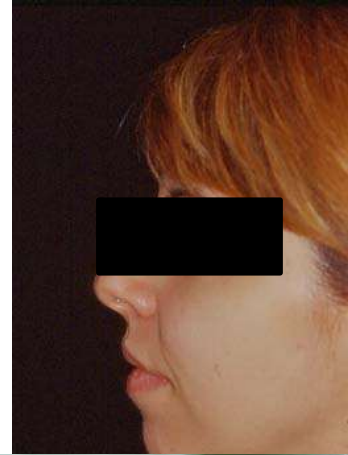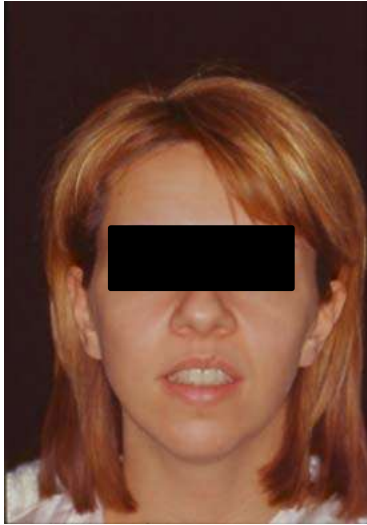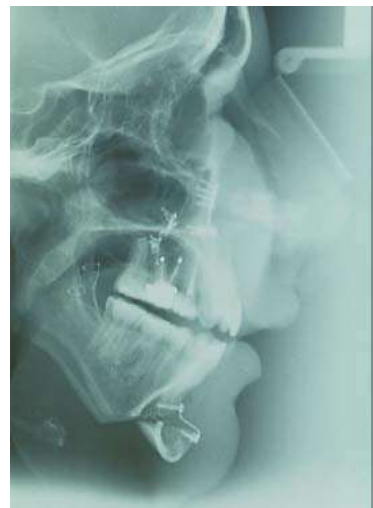
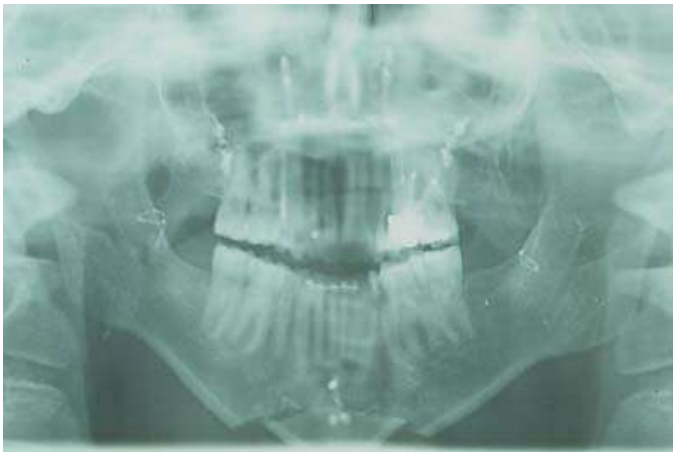
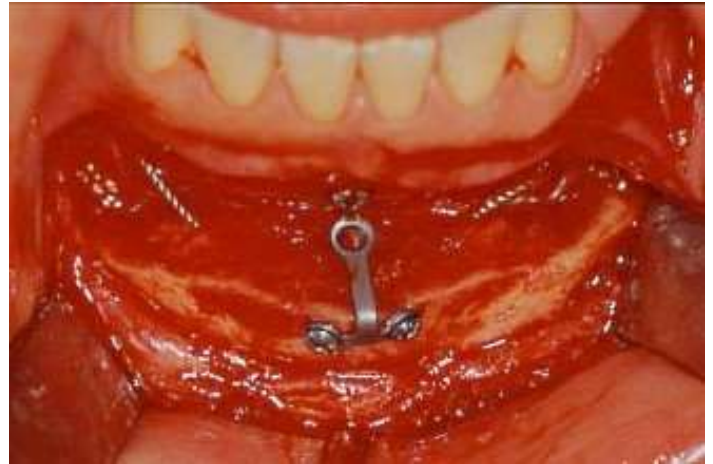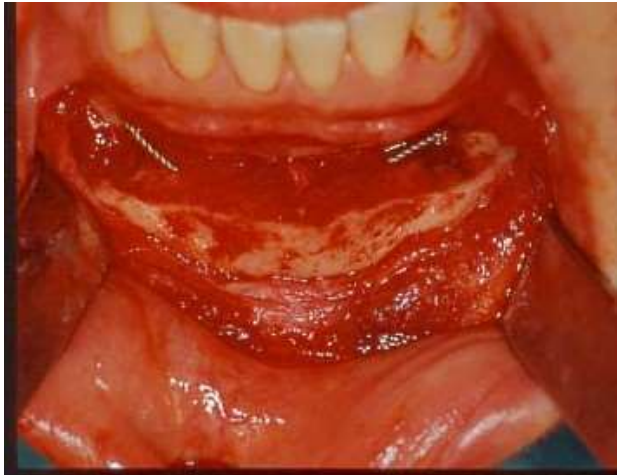criticità

- ***Incisione mucosa corretta***
- ***Ricorda anatomia NAI***
- ***Osteotomia sicura bordo distale***
- ***Attenzione con gli scalpelli***
- ***Sutura-Contenzione cutanea elastica***

Caso clinico



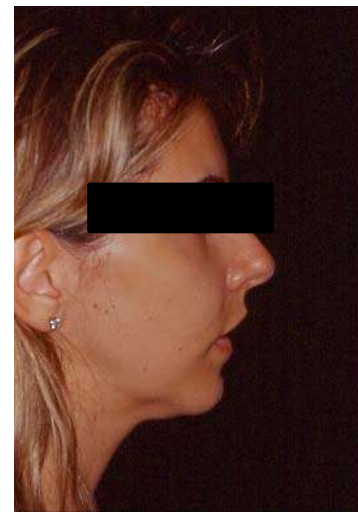
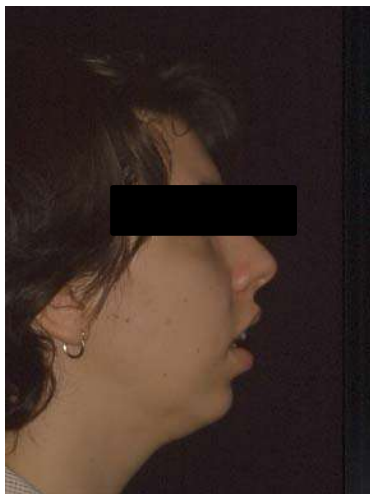
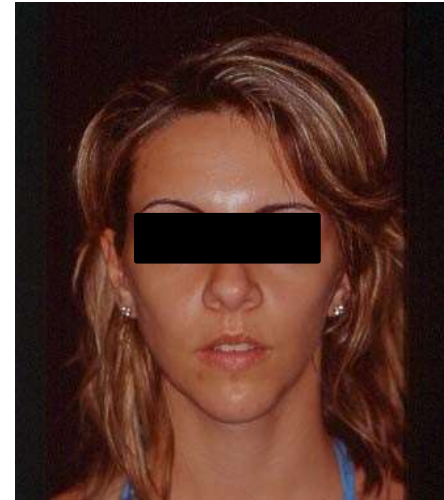
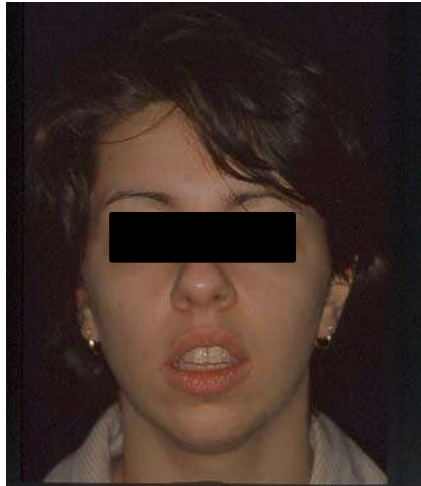
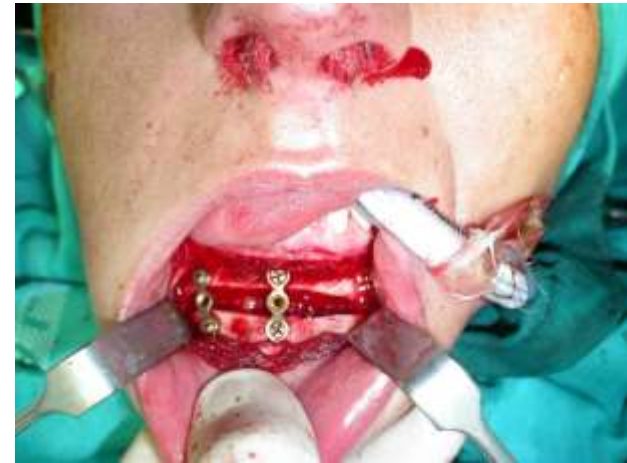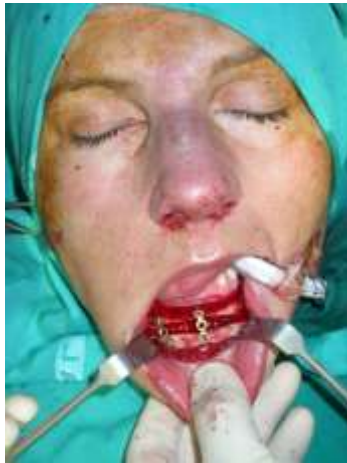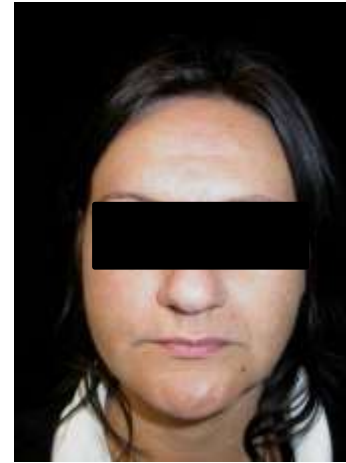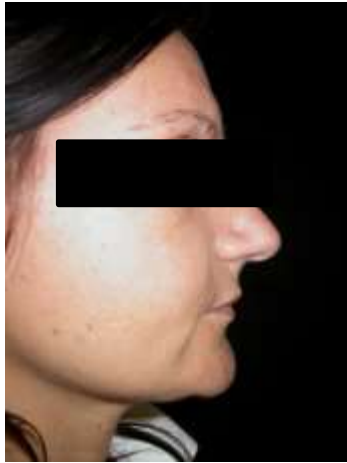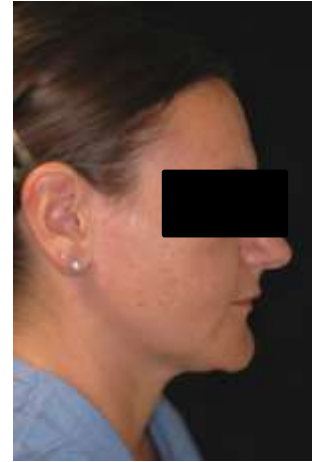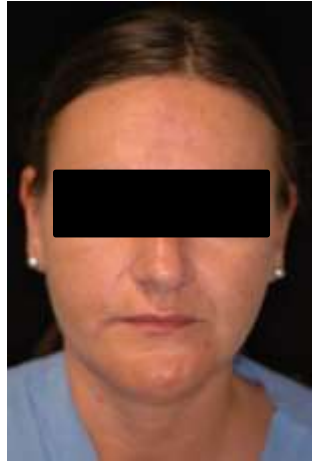PRIMA

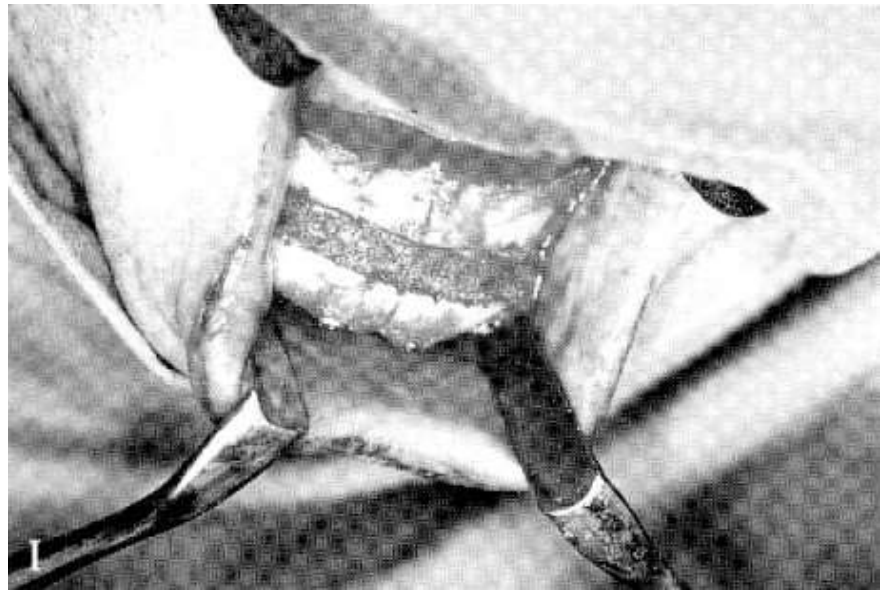

E

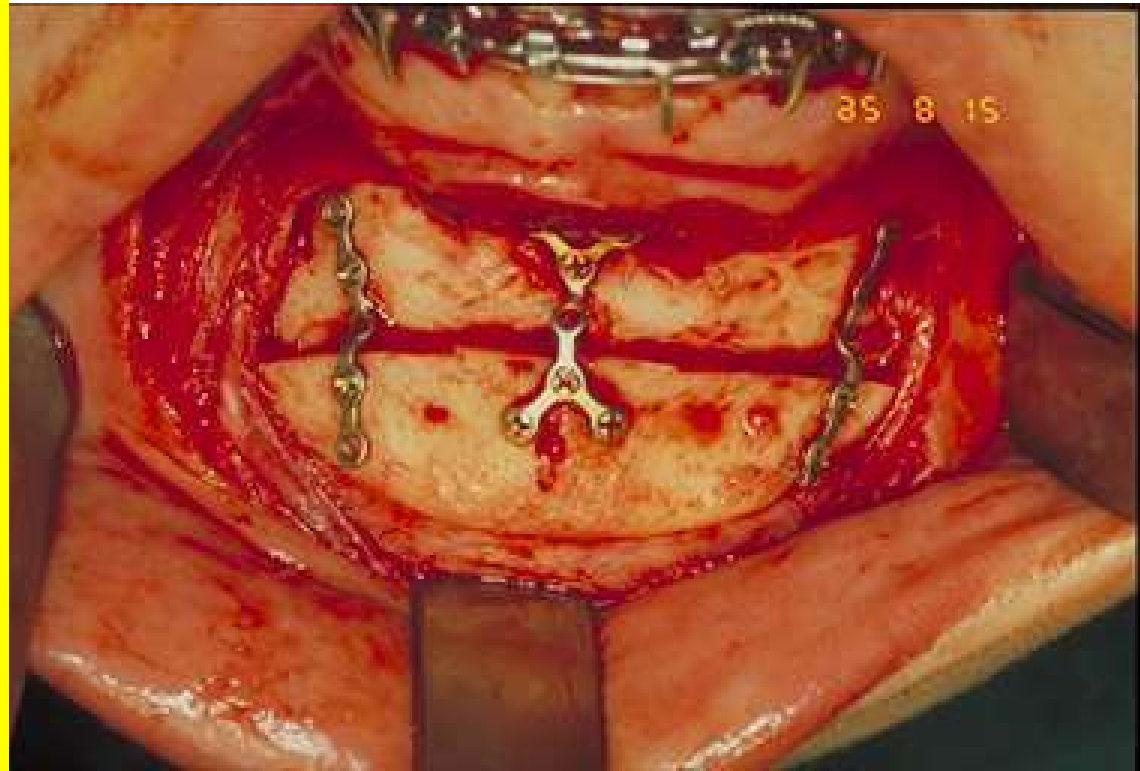
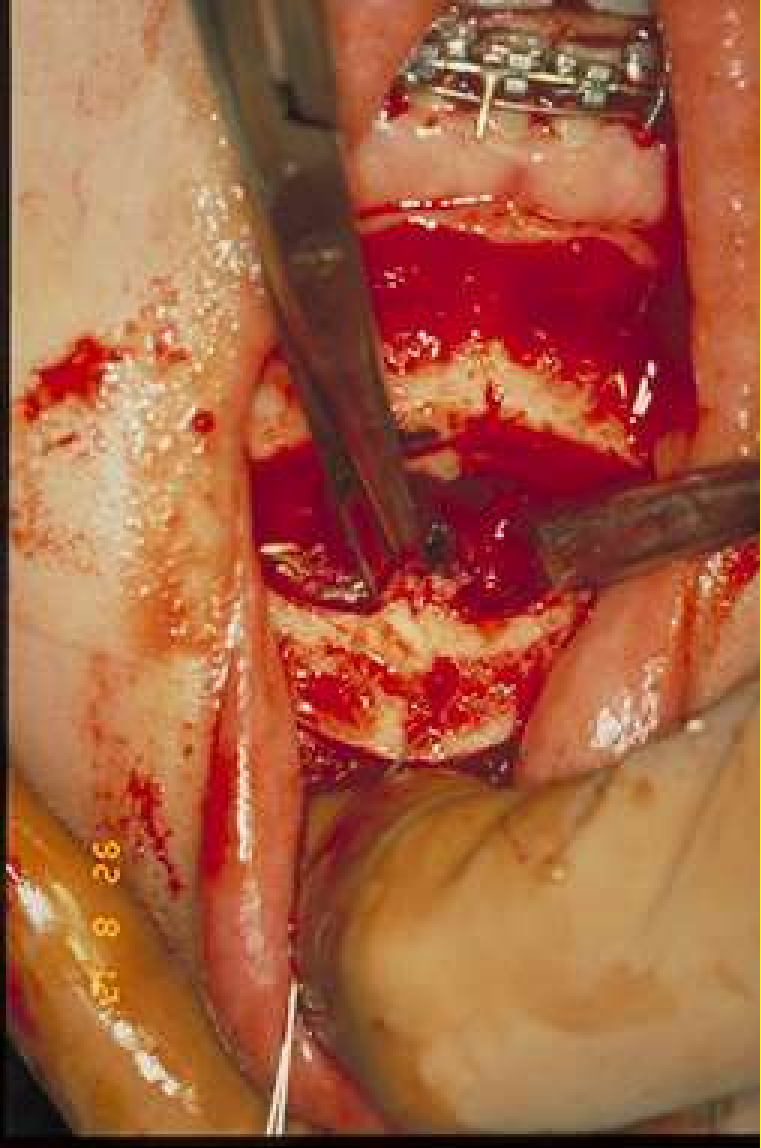
DOPO

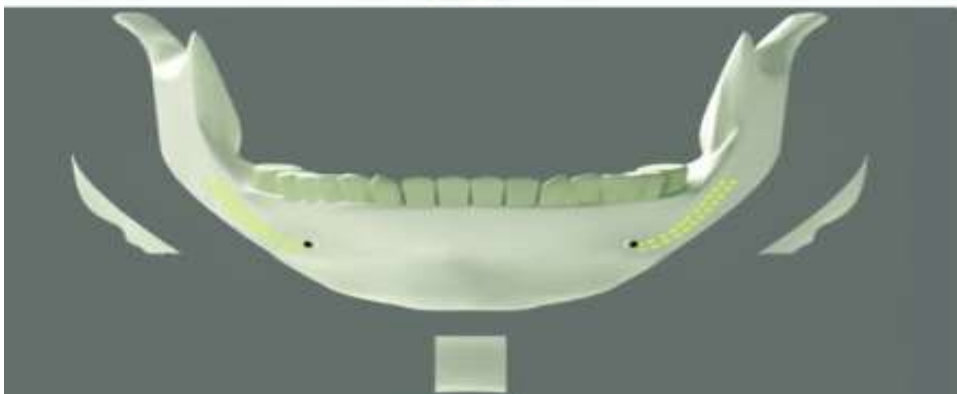


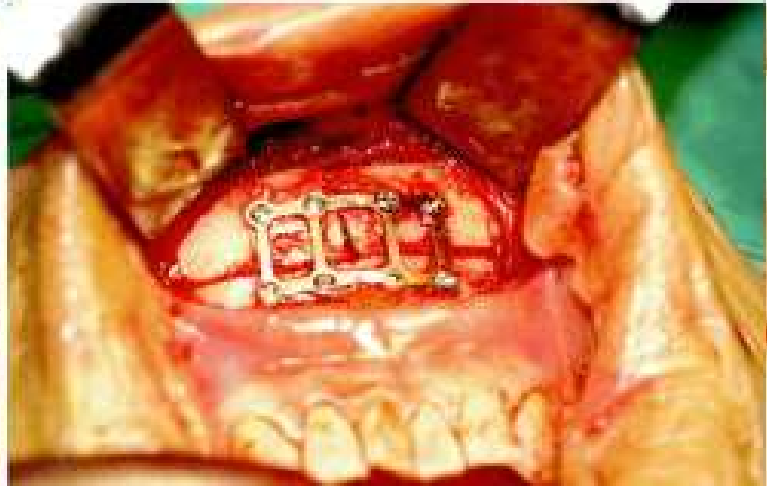
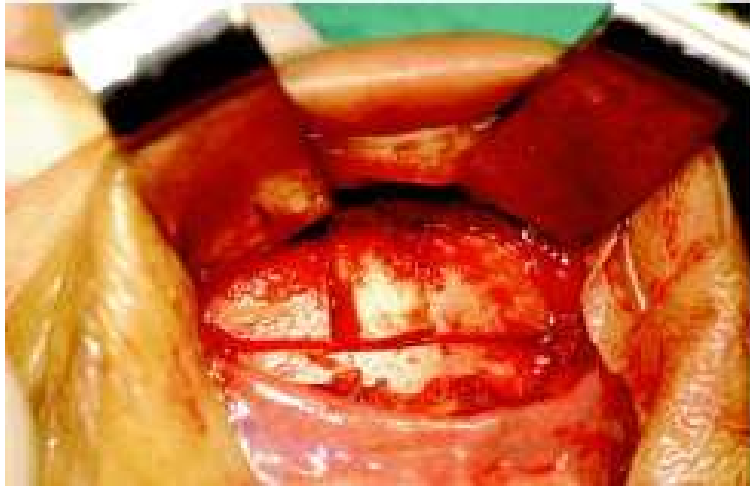
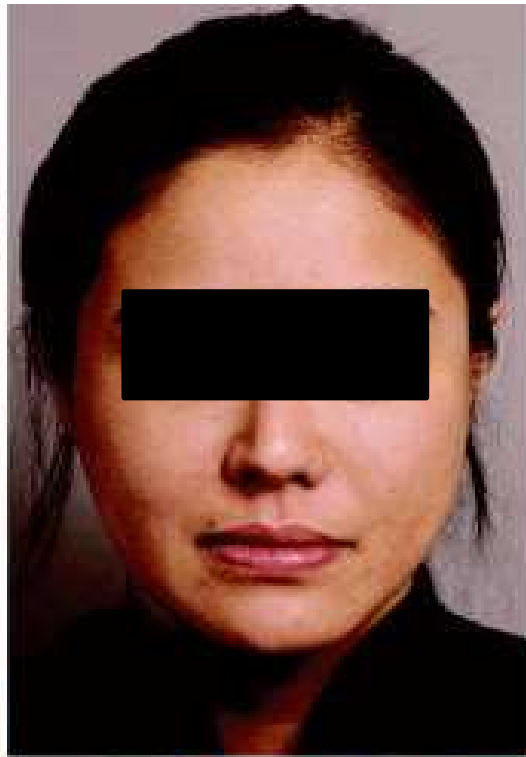
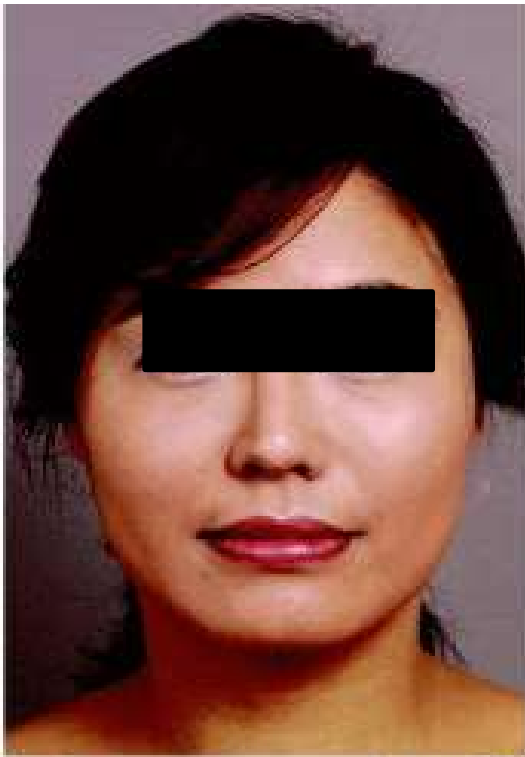


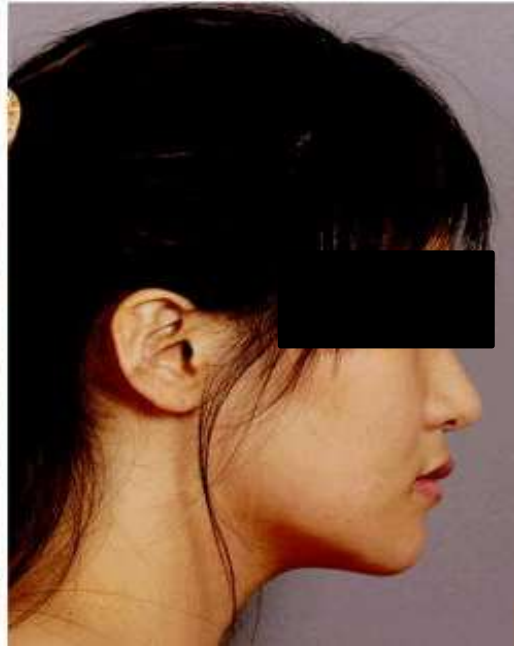
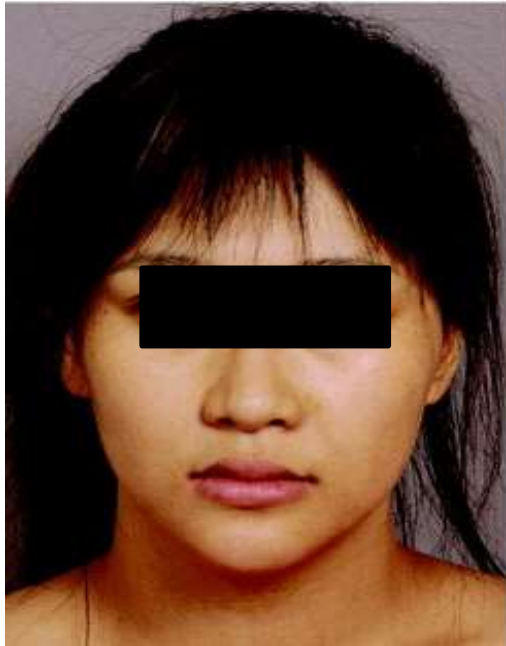
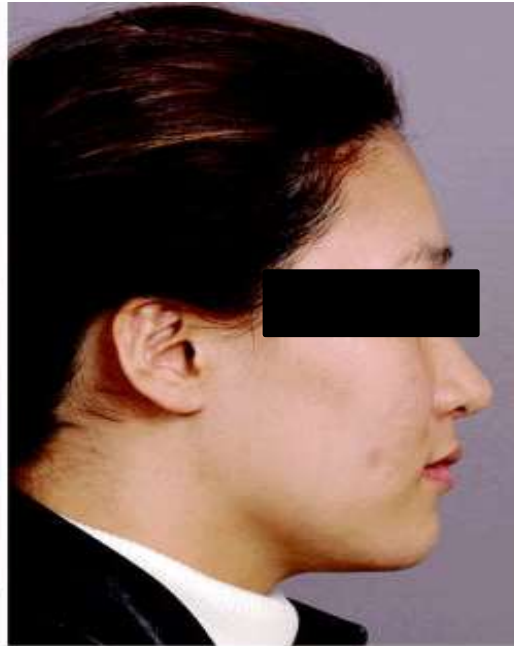
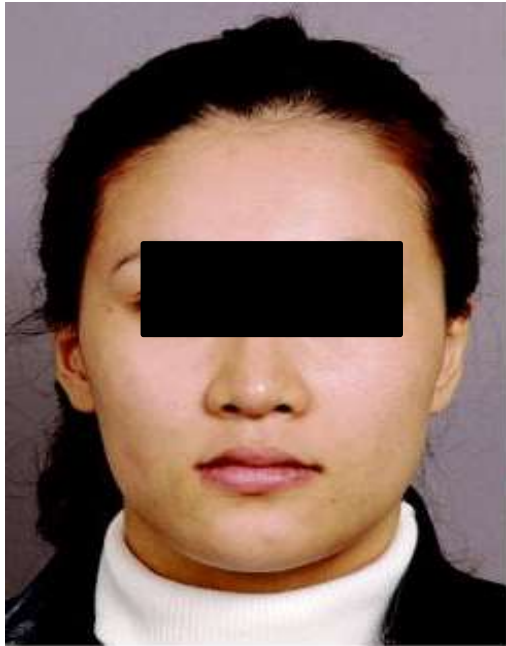




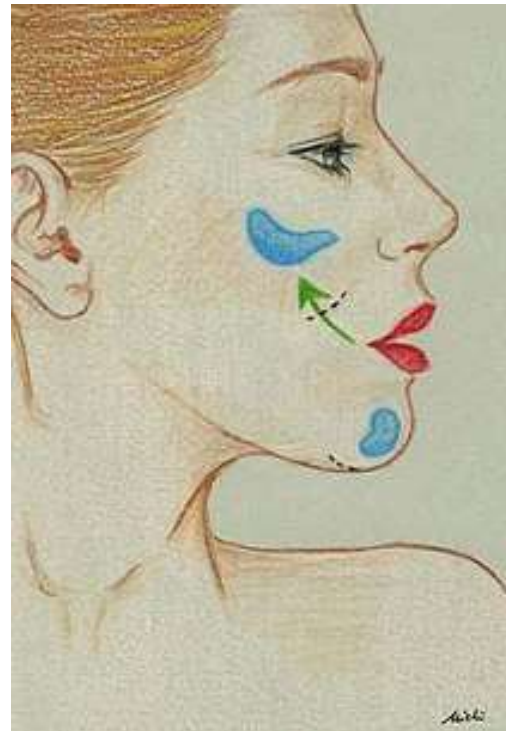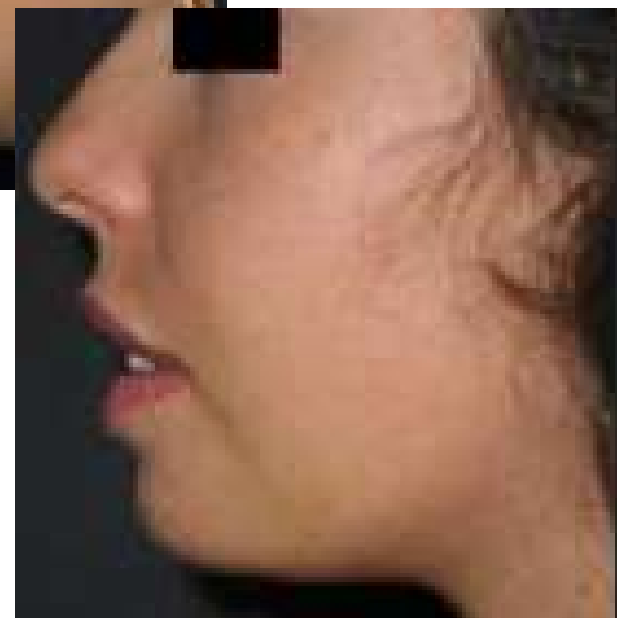
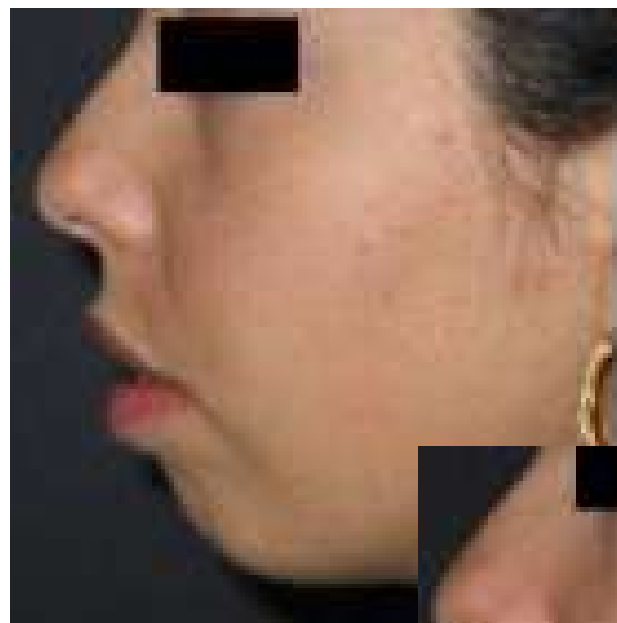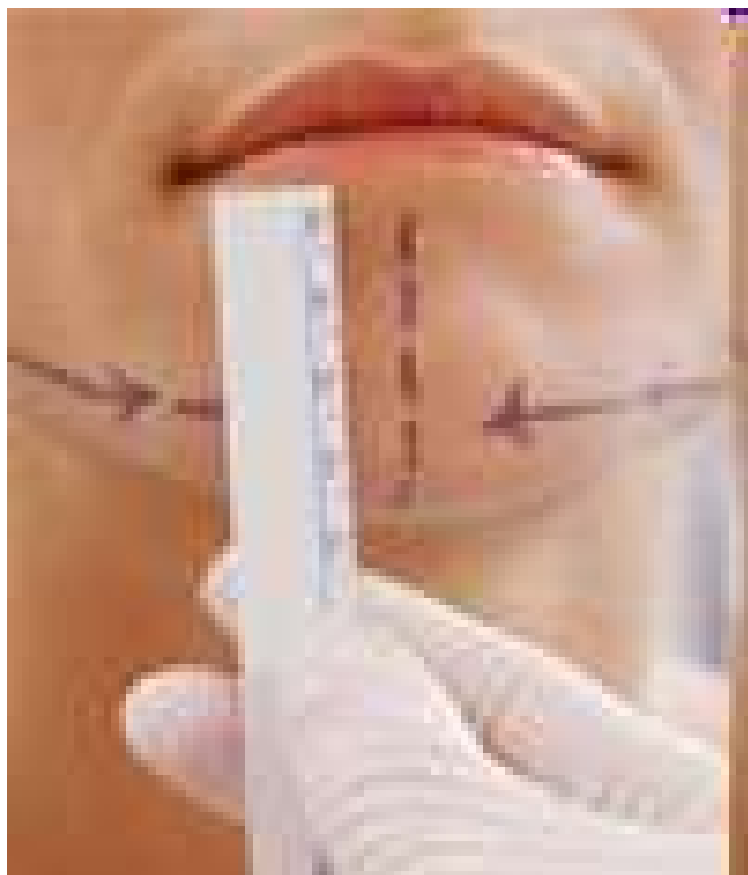


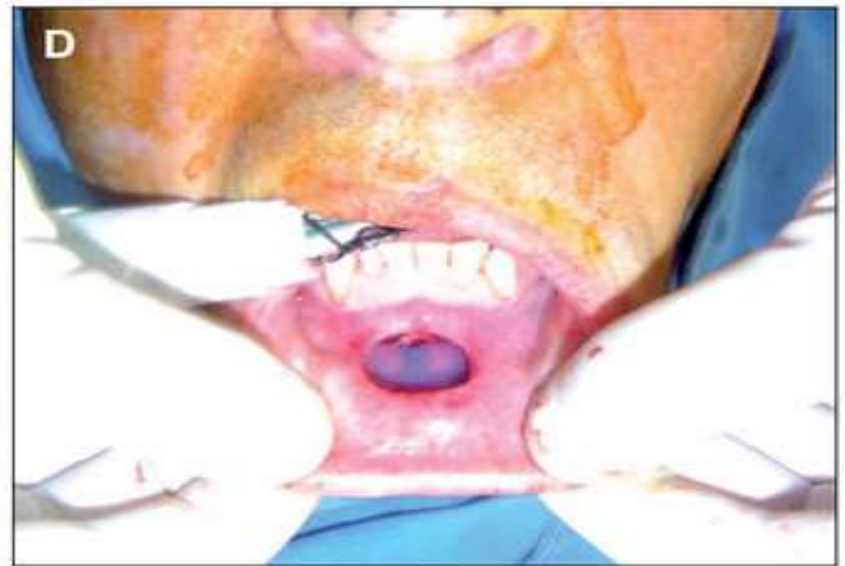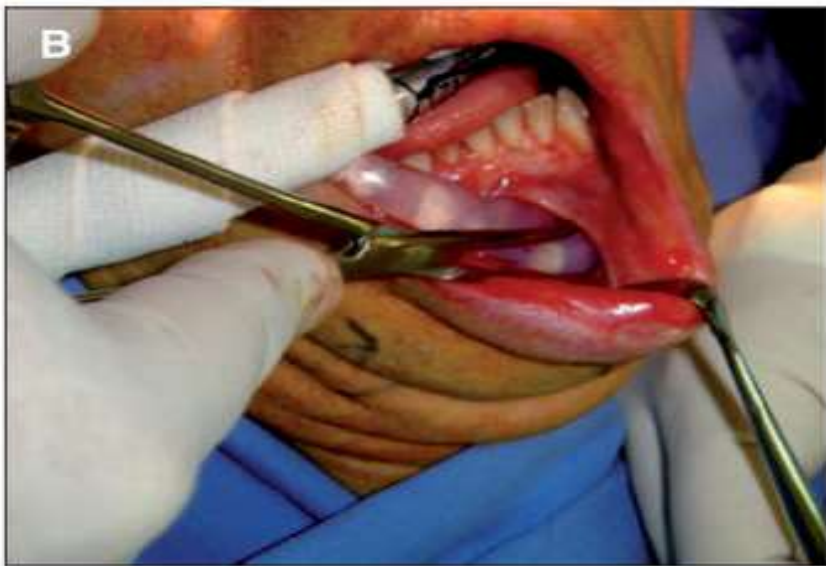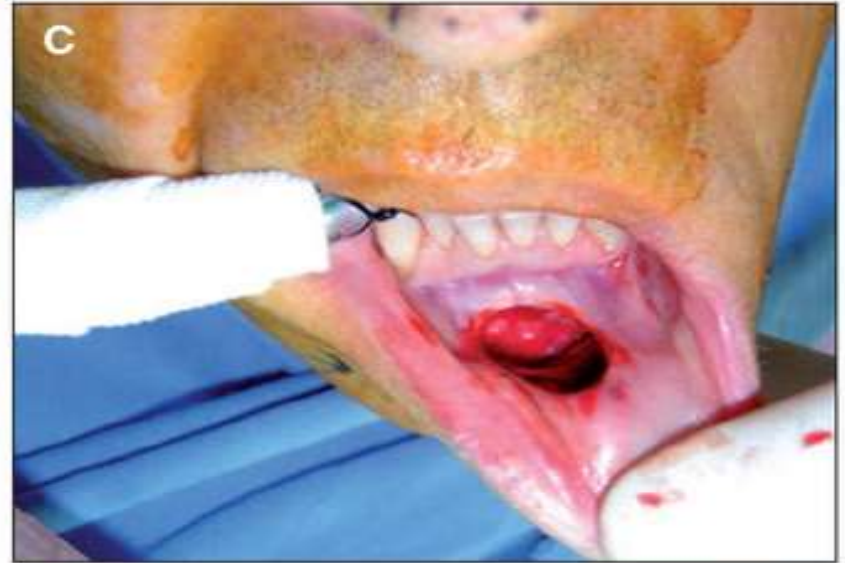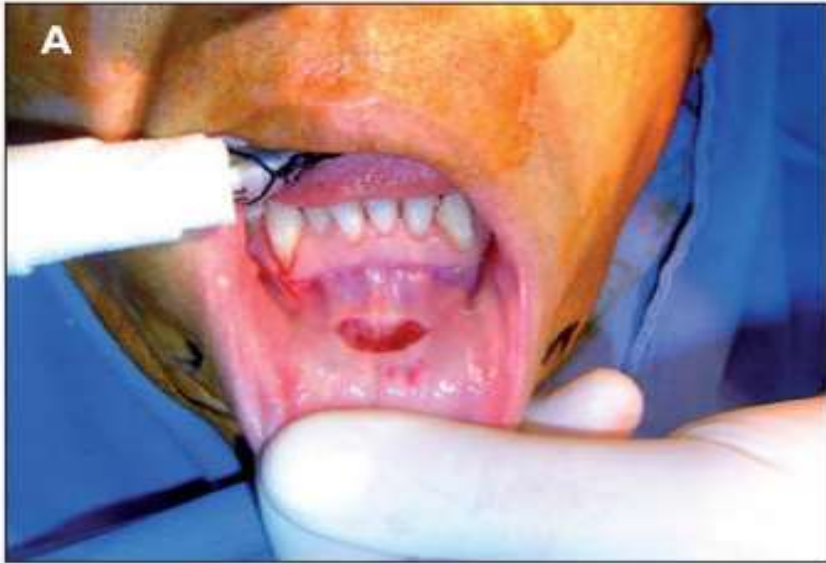Mento largo

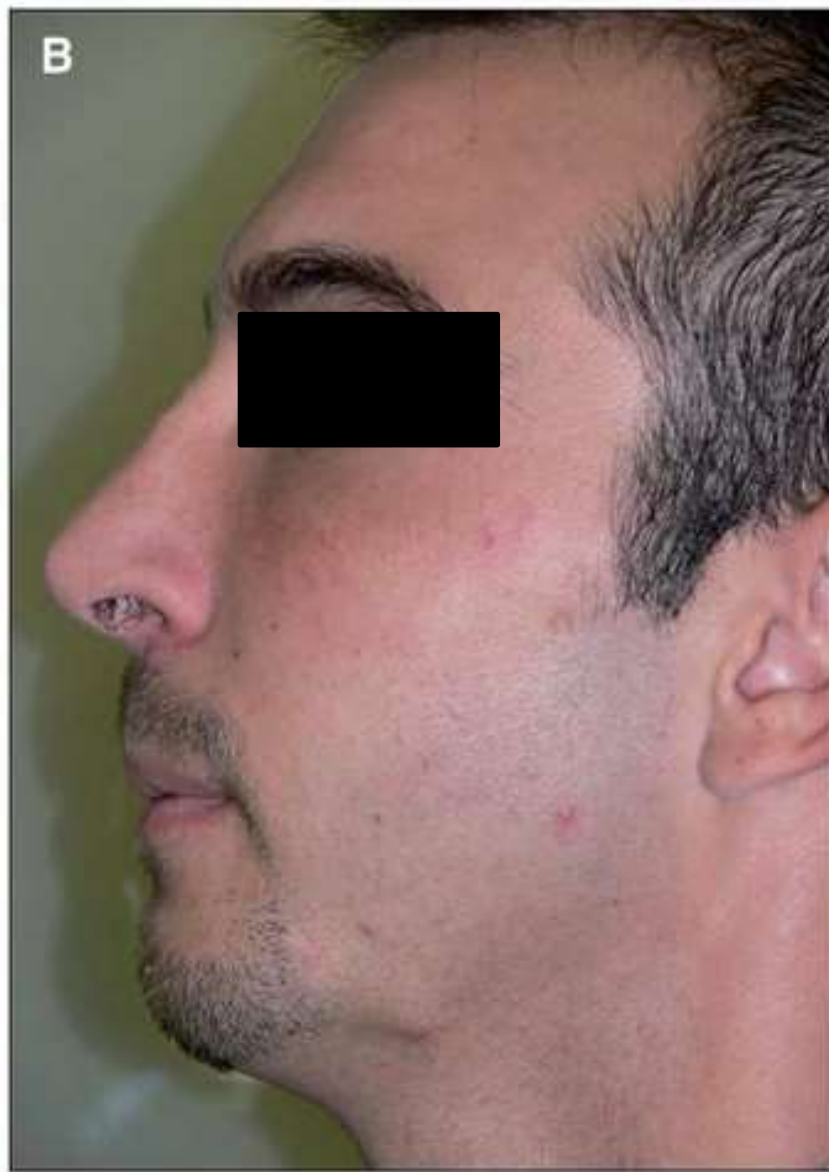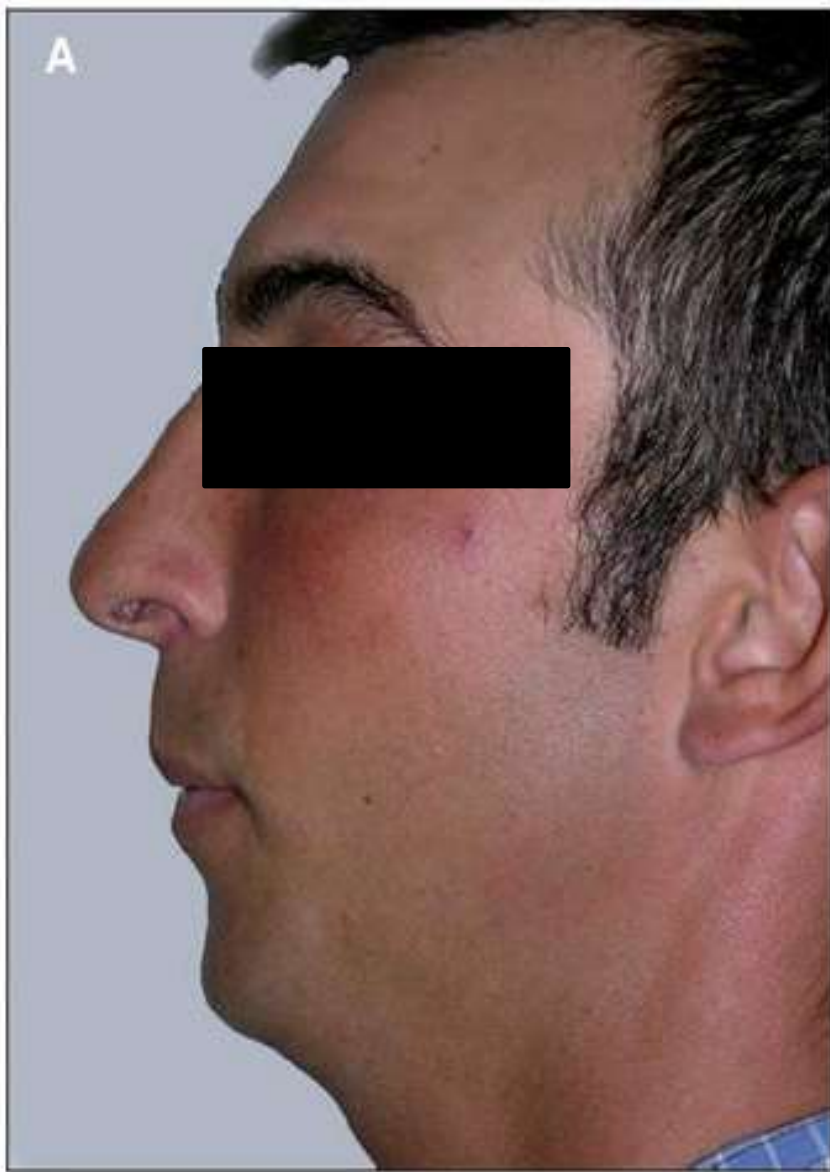INNESTI SILICONE MENTO E MANDIBOLA



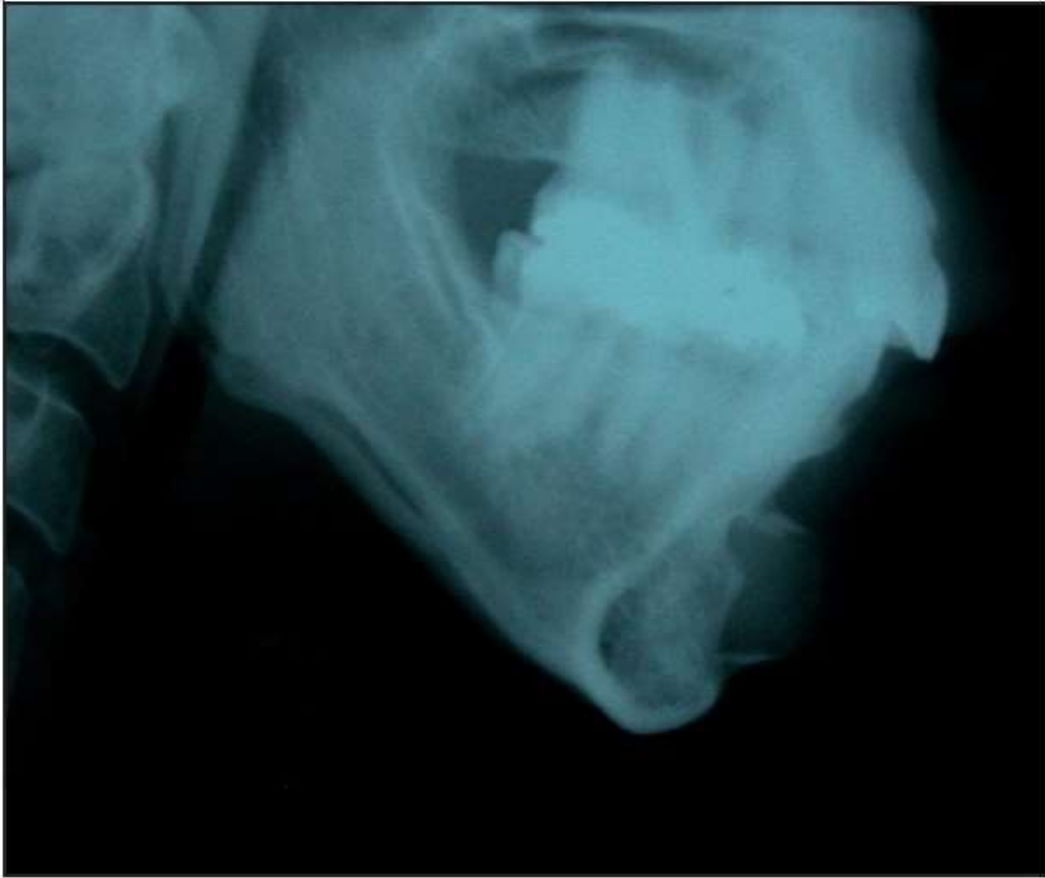INTERVENTI “LIGHT”

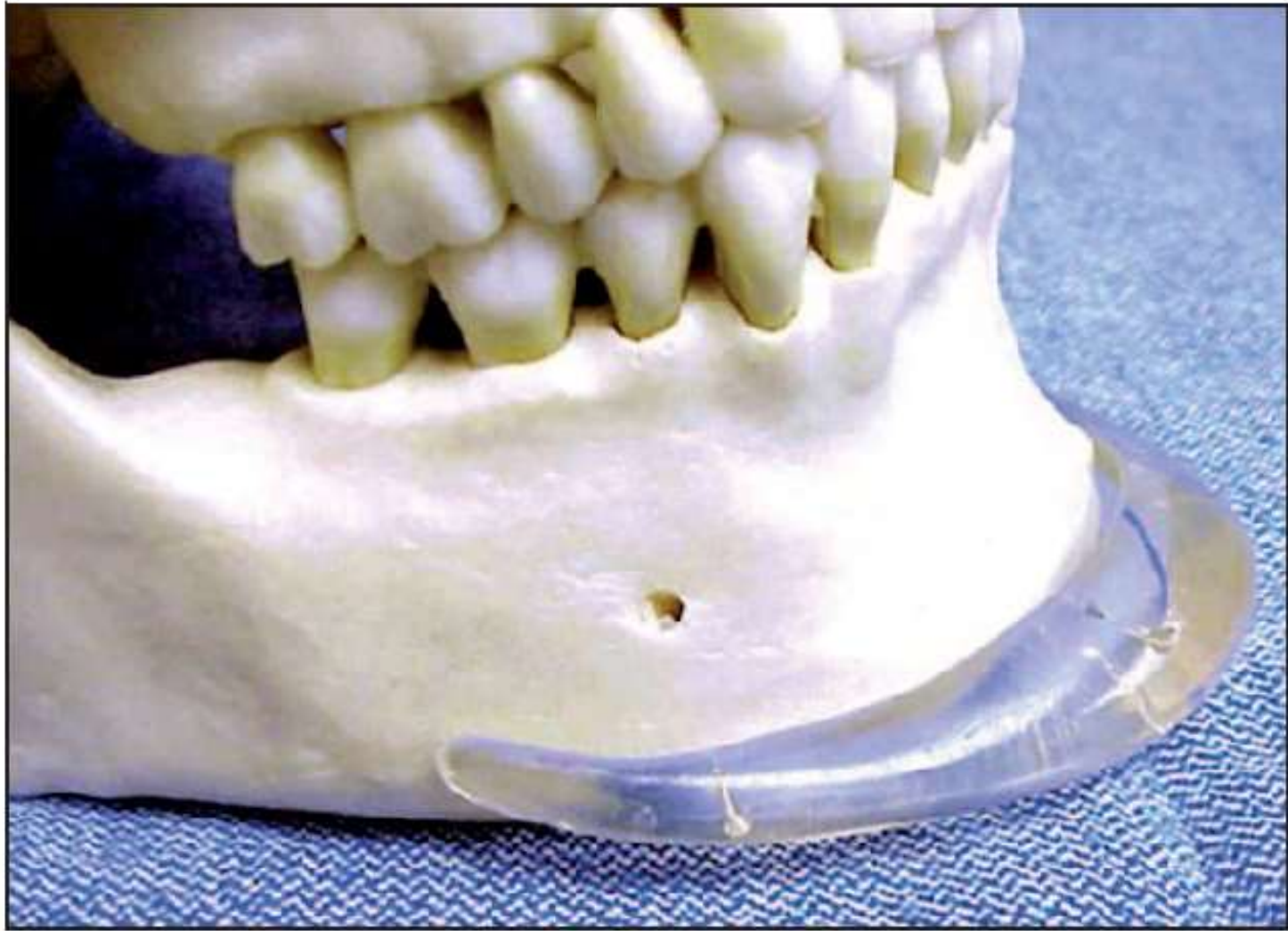




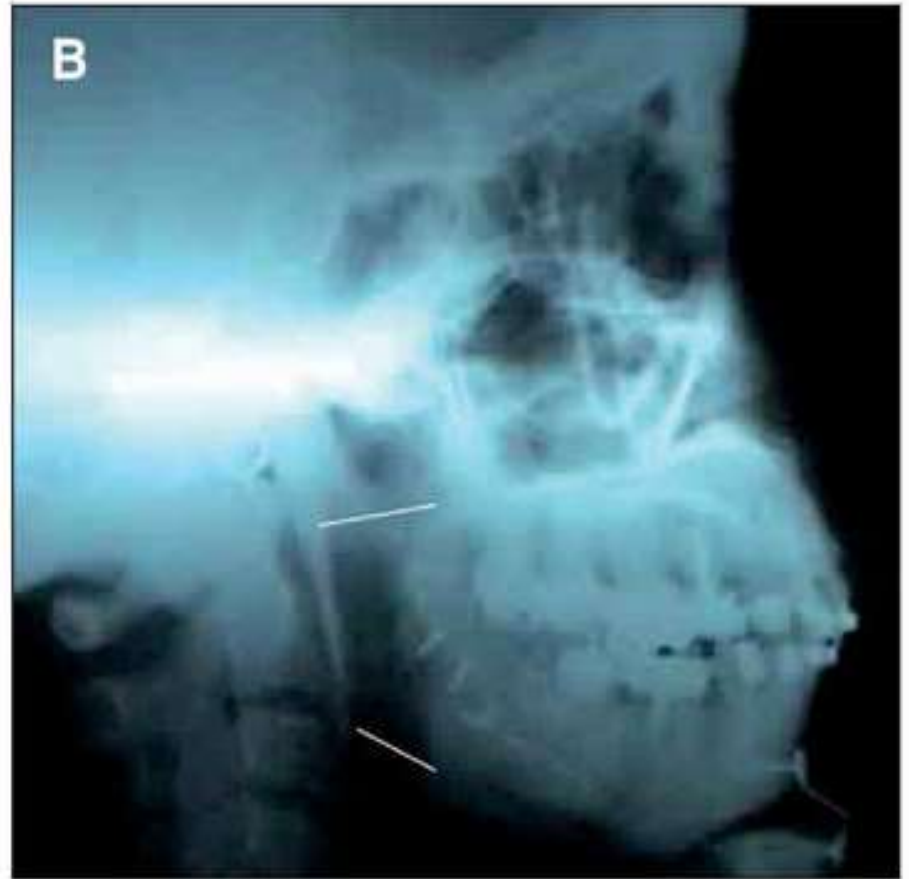
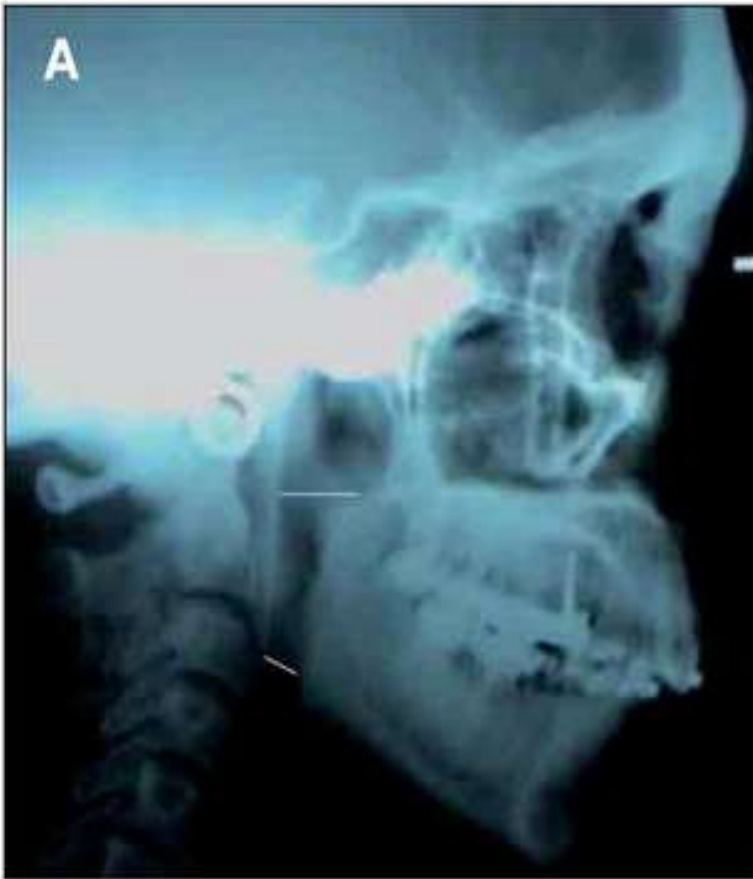

RIASSORBIMENTO OSSEO





AUMENTO DELLO SPAZIO RETROFARINGEO MEDIANTE MENTOPLASTICA DI AVANZAMENTO



VIE DI ACCESSO POSIZIONAMENTO INNESTI POLIETILENE

