

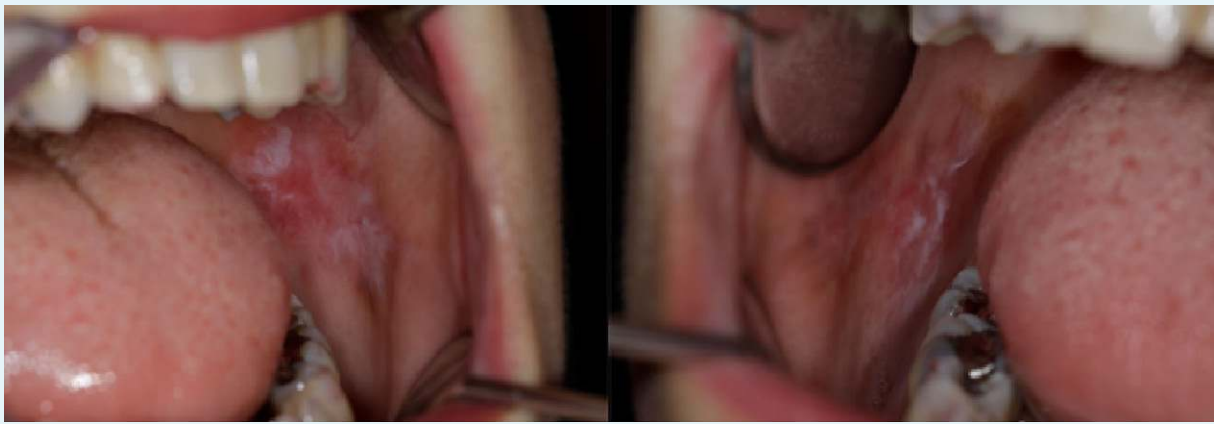
# White striae and erosions of the oral mucosa, but it is not oral lichen planus

M. Val\*, M. Gobbo, M. Rossi, M. Ragazzo, L. Guarda Nardini

Unit of Oral and Maxillofacial Surgery, Ca Foncello Hospital, Treviso, Italy.

\*Corresponding author: [matteo.val@outlook.it](mailto:matteo.val@outlook.it)

**Figure 1.** *Clinical aspect of Follicular lymphoid hyperplasia*



## CASE REPORT

A 45-year-old female non-smoking patient came to our hospital complaining of relapsing-remitting pain on bilateral buccal mucosa. She was suffering from Hashimoto's thyroiditis, but was not under any replacement therapy. She had bimaxillary orthognathic surgery several years ago.

Clinical examination revealed the presence of bilateral atrophic lesions surrounded by white striae, involving the buccal mucosa (figure 1). The differential diagnosis for reticular changes of the buccal mucosa includes primarily lichen planus, lichenoid drug reaction, and contact allergy. We suspected symptomatic lichen planus and an incisional biopsy of the left buccal mucosa was performed.

## WHAT IS YOUR DIAGNOSIS?

See page 147 for the answer to this photo quiz.