# Application of Amniotic Membrane in Temporomandibular Joint Arthroplasty

*Clinical Outcomes and Therapeutic Perspectives*




**Luca Guarda-Nardini, MD, DDS**

Director of the Unit of Oral and Maxillofacial Surgery
Director of the Regional Centre for Temporomandibular Joint Disorder
Treviso Regional Hospital — Ca' Foncello, Italy


*Findings from a randomized clinical trial — in press, J Oral Maxillofac Surg*

PRESENTATION ROADMAP

# Outline

01

## TMJ Arthroplasty

Indications, techniques, and the role of interpositional materials

02

## Human Amniotic Membrane

Biological properties and medical applications

03

## The Treviso RCT

Materials, methods, results, and safety

04

## Discussion & Perspectives

Clinical implications and future research directions





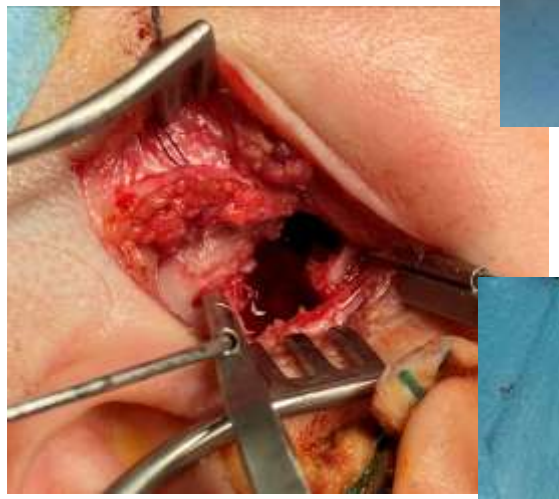



# Open TMJ Arthroplasty — Indications & Techniques

WHEN IS IT INDICATED?

## Intraarticular Pain & Dysfunction (IPD)

- Persistent intraarticular pain or mechanical dysfunction
- Refractory to standardized non-surgical therapy
- Failure of arthrocentesis with hyaluronic acid
- Most frequent substrate: TMJ osteoarthrosis
- Confirmed on 3-T MRI with structural derangement

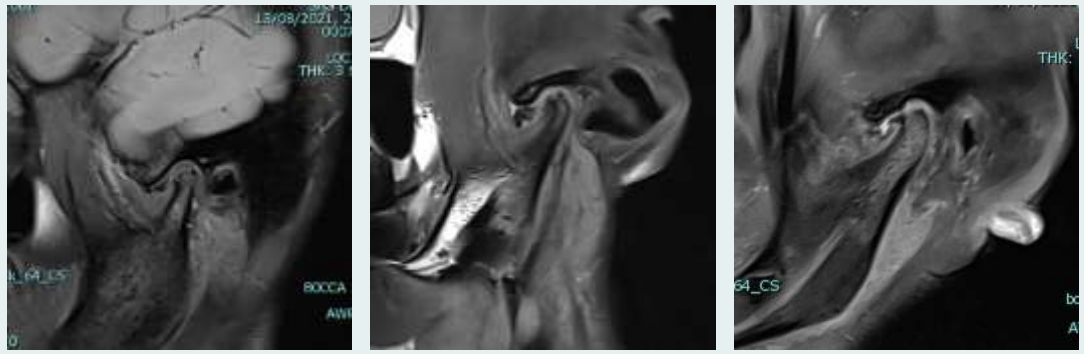

SURGICAL APPROACHES

## Arthroplasty Techniques

- Disk Repositioning
- Discectomy (meniscectomy) — disc removal
- Gap arthroplasty — condylar resection
- Interpositional arthroplasty — biologic / alloplastic spacer
- Total joint replacement — end-stage disease
- *Goal: pain control and restoration of mandibular function*



*Bouloux GF et al. J Oral Maxillofac Surg 2024;82:623 · Guarda-Nardini L et al. J Oral Facial Pain Headache 2021;35:113 · Andrade NN et al. Br J Oral Maxillofac Surg 2020;58:970*

# Indications — Limits of the Wilkes Classification

## *Does the Wilkes Classification address a treatment protocol?*

### KEY LIMITATIONS

- Provides a staging criterion for TMJ internal derangements
- Does NOT account for: lateral pterygoid muscle (LPM), joint effusion, degenerative disc changes, condylar translation, or retrodiscal layer integrity (pseudodisk)
- Focuses only on anterior disk displacement — posterior displacement and its associated pathology are ignored
- **No treatment protocol proposed for patients at different stages**

### REFERENCE STUDY

*Sci Rep. 2021;11:20917*

**Classification of TMJ internal derangement based on MRI and clinical findings of 435 patients contributing to a nonsurgical treatment protocol**

*Hegab AF, Abd Al Hameed H, Karam KS*

PMID: 34686740 · PMCID: PMC8536688

DOI: 10.1038/s41598-021-00456-7

*Wilkes CH. Arch Otolaryngol Head Neck Surg 1989;115:469 · Hegab AF et al. Sci Rep 2021;11:20917*

# Interpositional Materials in TMJ Arthroplasty

*Goal: reduce intraarticular fibrosis, prevent ankylosis, modulate inflammation*

## Temporalis flap

Pedicled muscle / fascia. Most widely reported autogenous option.



## Dermis–fat graft

Autogenous; donor-site morbidity; variable resorption.



## Buccal fat pad

Locally available



## Alloplastic spacers

Silicone, Acrylic, Teflon, PTFE — historical concerns over wear and foreign-body reaction.

## Human Amniotic Membrane

Off-the-shelf, biologically active, no donor-site morbidity.



*Desai H et al. Br J Oral Maxillofac Surg 2022;60:1023 · Bazsefidpay N et al. J Craniomaxillofac Surg 2024;52:578 · Kumar V et al. Int J Oral Maxillofac Surg 2025*

# Human Amniotic Membrane — Biological Properties

*Innermost layer of the placenta — avascular, multipotent, low-immunogenic*

## Anti-inflammatory

Suppresses IL-1, IL-6, TNF-α; rich in IL-1Ra and TGF-β.

## Anti-fibrotic

Exosome-mediated; reduces myofibroblast activation and adhesions.

## Antimicrobial

β-defensins, elafin, secretory leukocyte protease inhibitor.

## Low-immunogenic

Lacks HLA-A, -B, -DR; minimal host reaction in allogenic use.

## Pro-epithelializing

Basement membrane scaffold; growth factors EGF, KGF, bFGF.

## Pluripotent matrix

Mesenchymal and epithelial stem cells; chondrogenic potential.

*Niknejad H et al. Eur Cell Mater 2008;15:88 · Mao Y et al. Int J Mol Sci 2021;22:2136 · Askari S et al. Cell Tissue Bank 2025;27:3*

# Medical Applications of HAM

**1940s**

## Ophthalmology

Ocular surface reconstruction, corneal/conjunctival defects, pterygium.

**1990s**

## Dermatology & Burns

Wound healing, chronic ulcers, burn coverage.

**2000s**

## Orthopaedics

Cartilage repair, knee osteoarthritis, tendon surgery.

**2010s**

## Spine & Neurosurgery

Anti-adhesive barrier in cervical and lumbar fusion.

**2010s+**

## Oral & Maxillofacial Surgery

MRONJ, TMJ ankylosis, condylar reconstruction, IPD.

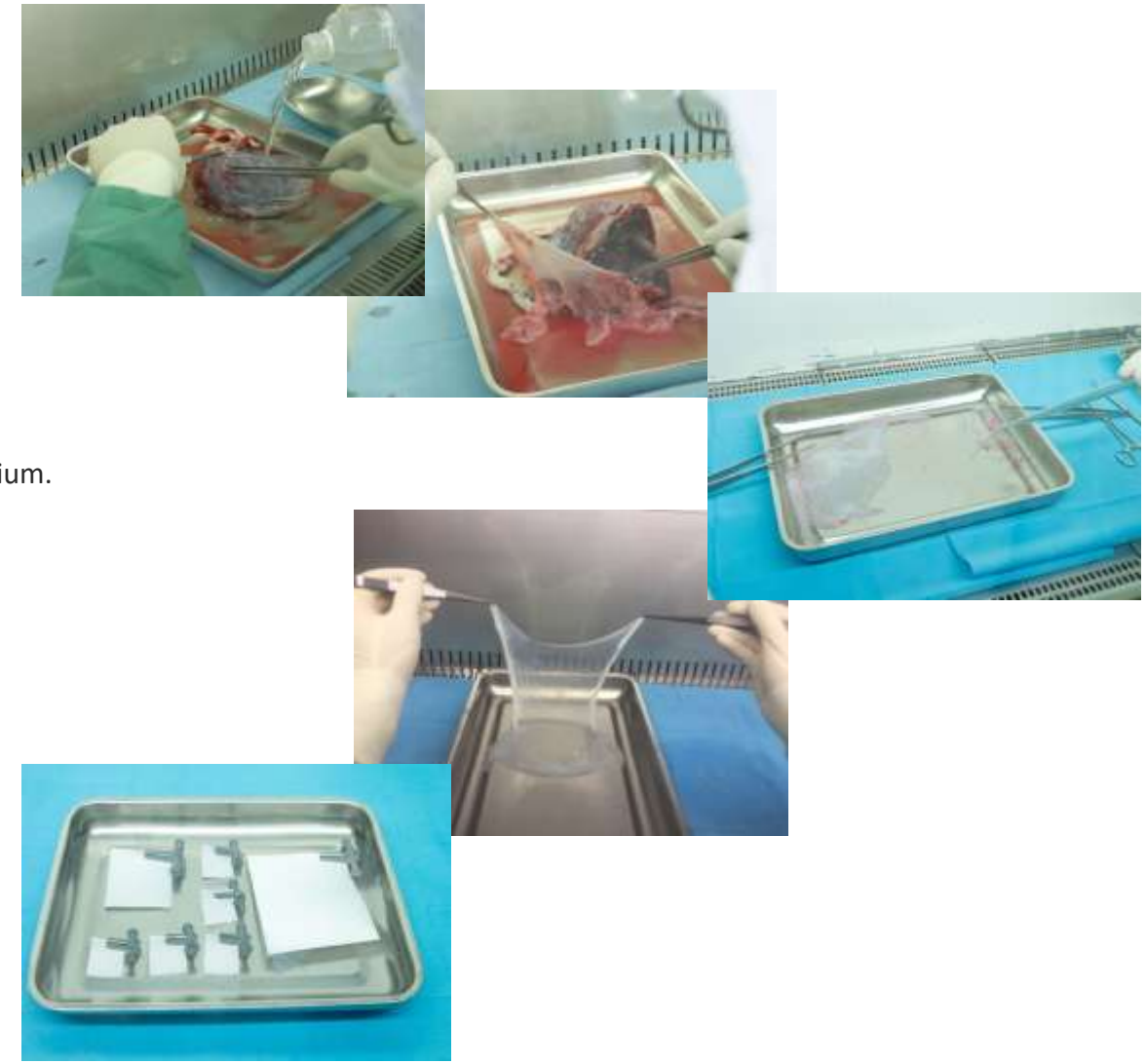

*In TMJ surgery: mostly post-traumatic / ankylosis cases — IPD evidence limited to small series*

*Akhter M et al. Oral Maxillofac Surg 2016;20:63 · Tuncel U et al. JOMS 2011;69:e58 · Natali S et al. J Clin Med 2022;11:3295 · Wu F et al. J Spine Surg 2025;11:256 · Ragazzo M et al. Cell Tissue Bank 2022;23:129 · Guarda-Nardini et. al Annal Maxillofacial surgery 2024,14(1)85-88 · Guarda-Nardini et al. Case Report Surg. 2019 Mar 3*

# Study Aim & Hypothesis

**AIM**

*To compare postoperative pain, mandibular function, and safety between TMJ arthroplasty with discectomy plus HAM interposition versus discectomy alone in TMJ IPD refractory to arthrocentesis.*

**HYPOTHESIS**

HAM interposition would be associated with greater pain reduction and greater improvement in mandibular function at 12 months versus arthroplasty alone.

## Why this trial?

- Most TMJ-HAM evidence is from ankylosis — biologically distinct from IPD
- IPD evidence limited to case reports and small uncontrolled series
- **No prior RCT has evaluated HAM interposition in TMJ IPD**

*Bouloux GF et al. JOMS 2024;82:623 · Lopez-Martos R et al. J Craniofac Surg 2020;31:e424 · Guarda-Nardini L et al. Case Rep Surg 2019:6037191*

# Materials & Methods — Study Design

| Single-centre RCT | Parallel-group, 1:1 | Single-blind (assessors) | Intention-to-treat | CONSORT 2025 |
|---|---|---|---|---|

POPULATION

## 62 subjects — Treviso (2017–2024)

- Adults ≥ 18 yrs with TMJ osteoarthrosis on 3-T MRI
- TMJ pain ≥ 6 months, VAS ≥ 4, impaired function
- Failed 5 weekly arthrocentesis + HA cycle
- Excluded: ankylosis, prior TMJ surgery, inflammatory arthritis
- **Allocation: 38 HAM vs 24 Control (consecutive enrolment)**




OUTCOMES (T0 vs T1 = 12 months)

## Pain · Function · Safety

- VAS pain (0–10) at rest, phonation, mastication
- MIO (spontaneous & passive); lateral excursion; protrusion
- Masticatory capacity (0–10 VAS)
- Complications: facial nerve, infection, ankylosis, reoperation







*Hopewell S et al. CONSORT 2025. BMJ 2025;389:e081123 · Guarda-Nardini L et al. J Oral Rehabil 2015;42:521 · Conti PC et al. J Oral Rehabil 2001;28:534*

# Surgical Technique & HAM Processing

## SURGICAL TECHNIQUE

1. **Preauricular approach**
   Subcutaneous dissection through SMAS; identification of temporal branch of facial nerve
2. **Capsulotomy**
   Vertical capsulotomy to expose the superior joint space
3. **Discectomy**
   Complete meniscectomy + debridement of fibrotic adhesions and osteophytes
4. **HAM interposition**
   3 × 3 cm cryopreserved patch over glenoid fossa, sutureless adaptation
5. **Layered closure**
   Capsule with 4-0 resorbable; physiotherapy starts on POD 3

## HAM PROCESSING (FBTV, Treviso)

### Tissue-Bank Workflow

- Donor: elective C-section ≥ 35 wks, full screening (HIV, HBV, HCV, etc.)
- EU-GMP grade-A processing; antibiotic decontamination 24 h
- Cut into 3 × 3 cm patches; cryoprotectant (DMSO + albumin)
- Programmed freezing to −140 °C; storage at −160 °C ($LN_2$ vapour)
- Thawed in saline on the back table immediately before use
- ***Turnaround: 48–72 h from request — no specialized OR infrastructure***



*Bauer F et al. Eplasty 2013;13:e17 · Lopez-Martos R et al. J Craniofac Surg 2020;31:e424 · Guarda-Nardini L et al. Case Rep Surg 2019:6037191*

# Results — Pain Outcomes (VAS 0-10) at 12 Months

**All comparisons P-value < .001 (statistically significant) — adjusted baseline, age, sex, laterality**



ADJUSTED β (HAM − Control)

**At rest**

**−2.82**

*95% CI −3.30 to −2.34*

**Phonation**

**−4.16**

*95% CI −4.72 to −3.60*

**Mastication**

**−3.06**

*95% CI −3.70 to −2.42*

*Conti PC et al. J Oral Rehabil 2001;28:534 (VAS scale) · Manuscript Tables 3 & 4 — in press, JOMS*

# Results — Function & Safety







### Maximum mouth opening (MIO)

Both groups converged at 12 months (≈ 34 mm spontaneous, 38 mm passive). Larger raw change in Controls = regression to the mean from a more impaired baseline.

*Manuscript Tables 3 & 4 — in press, JOMS · Post-hoc power > 99% for all significant comparisons (Cohen's d 1.45–3.62)*

## SAFETY PROFILE

**0**

Deep infections, ankylosis, sialocele, permanent facial-nerve palsy, reoperations, graft-related events

**10.5% vs 25.0%**

Transient frontal-branch facial-nerve weakness (HAM vs Control) — all resolved within 12 weeks (P-value = .2, no statistical evidence of differences HAMvsControl)

**0**

Immunologic or allergic reactions attributable to HAM

# Discussion — Putting the Findings in Context

## KEY MESSAGES

### Pain reduction exceeds minimal clinically important difference (great efficacy in pain management!)

Adjusted VAS difference of −2.8 to −4.2 points exceeds the ≈1.5–2 point minimal clinically important difference for orofacial pain.

### Biological — not mechanical — effect

Benefit on fine excursive motion and pain, not on maximum opening. Consistent with HAM as an anti-inflammatory / anti-fibrotic interface, not a spacer.

### Practical advantages of HAM over autografts

Off-the-shelf tissue-bank product; no donor-site morbidity; minimal added operative time; no specialized OR infrastructure.

## LIMITATIONS

- Single-centre, single-team — limits generalizability
- Unequal allocation (38 vs 24); baseline imbalance corrected by ANCOVA, residual confounding possible
- No a priori sample-size calculation — exploratory and hypothesis-generating
- 12-month follow-up only — late effects unknown
- No structural verification of HAM persistence (no prospective MRI/biopsy protocol)
- Subjects and surgical team not blinded

*Bauer F et al. Eplasty 2013;13:e17 · Lopez-Martos R et al. J Craniofac Surg 2020;31:e424 · Mao Y et al. Int J Mol Sci 2021;22:2136 · Askari S et al. Cell Tissue Bank 2025;27:3*

04 • CONCLUSIONS

# Conclusions & Therapeutic Perspectives

### WHAT HAM DOES

Reduces pain and improves the QUALITY of joint motion — fine excursions and masticatory comfort — through anti-inflammatory and anti-fibrotic activity.

### WHAT HAM DOES NOT DO

It does not increase MAXIMUM mouth opening beyond what discectomy + physiotherapy alone can achieve.

### WHERE IT FITS

Safe, off-the-shelf adjunct for IPD refractory to arthrocentesis and HA. Negligible added operative time, no donor-site morbidity, no detected additional morbidity.

### FUTURE DIRECTIONS

- Multicentre confirmatory RCT and longer follow-up
- Prospective imaging / biopsy protocol to verify membrane persistence and biological mechanism
- Head-to-head comparison with other autogenous interpositional materials in IPD

# Thank you

**Luca Guarda-Nardini, MD, DDS**

Department of Oral and Maxillofacial Surgery

Treviso Regional Hospital — Ca' Foncello, Italy

*Acknowledgments: Fondazione Banca dei Tessuti del Veneto (FBTV) · Maxillofacial physiotherapy and outpatient teams, Treviso Regional Hospital*